

## PARADUODENAL HERNIA- AN OBSCURE AND PERILOUS CAUSE OF INTESTINAL OBSTRUCTION.

Dr. Rajesh Kumar Soni<sup>1</sup>, Dr. Dharmendra K Pate<sup>2</sup>, Dr. Ashwani Gupta<sup>3</sup>, Dr. Raghav Garg<sup>4</sup>, Dr. Ratnakar Namdeo<sup>5</sup>

<sup>1,3</sup> Professor, Department of Surgery, VMMC and Safdarjung Hospital, New Delhi

<sup>2</sup> Specialist, Department of Surgery, VMMC and Safdarjung Hospital, New Delhi

<sup>4,5</sup> Senior Resident, Department of Surgery, VMMC and Safdarjung Hospital, New Delhi

**Article Info:** Received 06 June 2020; Accepted 28 June 2020

**DOI:** <https://doi.org/10.32553/ijmbs.v4i7.1222>

**Corresponding author:** Dr. Rajesh Kumar Soni

**Conflict of interest:** No conflict of interest.

### Abstract

Paraduodenal hernias (PDH) constitute more than half of internal hernias. Both left and right PDH occur due to error of rotation of gut and defective fusion of mesocolon and mesentery with posterior parietal peritoneum. Clinical diagnosis of PDH is very difficult because of its varied presentation and nonspecific symptoms. Prompt diagnosis and surgery is imperative to avoid strangulation of bowel which is associated with high mortality. Before the advent of CECT many were discovered during exploratory laparotomy or unrelated abdominal surgery. Now CECT abdomen has become the gold standard for pre-operative diagnosis of PDH. We report two cases of PDH, one on left side and another on right side, diagnosed preoperatively and treated successfully.

**Keywords:** Paraduodenal hernia, Mesocolic hernia, Treitz hernia, Internal hernia

### Introduction

Congenital internal hernia is a rare condition in which there is protrusion of viscera through a normal or abnormal opening in peritoneal or mesenteric folds. Paraduodenal hernia (PDH) constitutes about 30 -50% of all internal hernias. These are also known as Treitz hernias and are caused by an abnormal rotation of the midgut and failure of fusion of mesocolon and posterior parietal peritoneum in left PDH and failure of fusion of proximal jejunal mesentery in right PDH[1].

Left sided PDH is more common, generally occurs in male and has 50% life time risk of developing small bowel obstruction with 20-50% mortality [2].

PDH are difficult to diagnose clinically because of variable and non-specific symptoms. The patient may remain asymptomatic throughout the life or present with recurrent pain abdomen (43%), or may present with symptoms of acute intestinal obstruction [3].

Early diagnosis and prompt surgical treatment is required to prevent serious complications like bowel gangrene which is associated with high mortality. We hereby report two cases of PDH diagnosed pre-operatively and successfully managed by laparotomy.

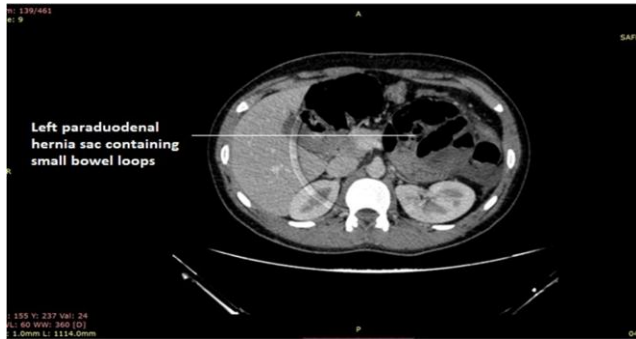
### Case Presentation

### Case-1

A seventeen year old male presented to the emergency department with complaints of pain in left upper abdomen associated with nausea and vomiting. Pain was intermittent, colicky and relieved on sitting. There was history of similar episodes in the past which were relieved spontaneously or with simple antispasmodics. There was no history of trauma, alcoholism, drug abuse or previous surgery. There was no history of jaundice, tuberculosis or any other comorbidity.

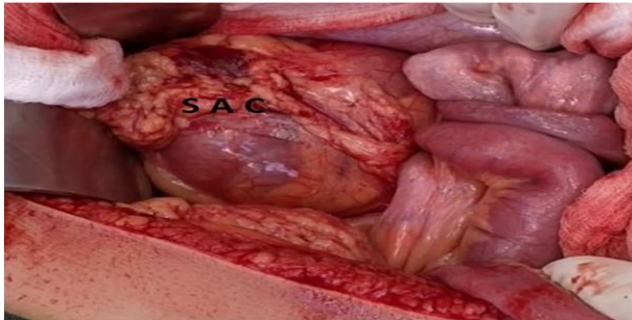
Patient had normal vital signs. There was tenderness and mild guarding in left hypochondrium and left lumbar region. An ill-defined firm mass was palpable in left side. Bowel sounds were exaggerated. Hernial sites were normal.

All routine hematological and biochemical investigations were within normal limits. Plain x-ray abdomen showed multiple air-fluid levels consistent with small bowel obstruction. Ultrasonography [USG] findings were suggestive of intestinal obstruction. CECT abdomen revealed encapsulated small bowel loops posterior to the stomach lying left and above the fourth part of duodenum. There was no vascular compromise [Fig.1]. A diagnosis of Left Paraduodenal hernia was made and patient was taken for surgery.



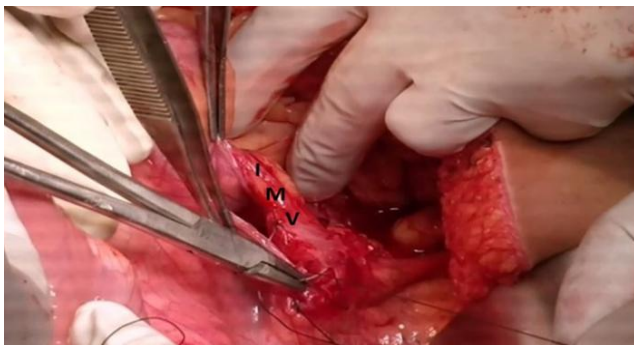**Figure 1:** CECT film showing left paraduodenal hernia

Operative findings were consistent with the pre-operative diagnosis of left PDH. Approximately two-three feet of proximal small bowel was herniated behind the transverse and left mesocolon through 5-6 cm. defect on left side of Treitz's ligament behind the inferior mesenteric vein, which was forming the anterior border of defect [Fig.2]



**Figure 2:** Sac containing small bowel loops

The small bowel was easily reduced and its viability confirmed. The defect in the root of the mesentery and left mesocolon was sutured with non-absorbable suture going right up to the ligament of treitz's and base of mesocolon taking care not to injure or puncture inferior mesenteric vein [Fig-3].



**Figure 3:** Primary repair of hernia opening with IMV at anterior border of defect

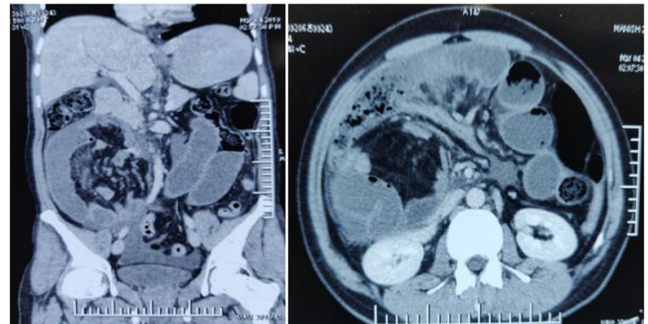
Abdomen was closed without any drain. Post-operative period remained uneventful and patient was discharged on third post-operative day.

## Case-2

A 23 year old male presented to the surgical emergency with complaints of pain right side of abdomen for last one month. Pain was intermittent, colicky in nature and increased for the past two days with vomiting. There was no history of similar complaints in the past and patient was not investigated earlier.

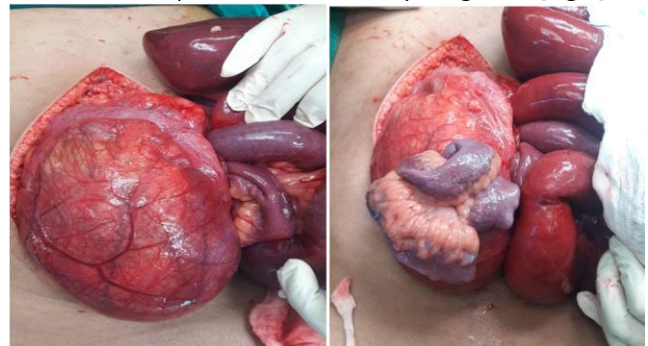Patient's vital signs were normal. Abdominal Examination revealed fullness in the right iliac and right lumbar region. There was tenderness in the right iliac fossa, though no lump was palpable. Bowel sounds were increased.

All haematological and biochemical investigation were normal. Plain X-ray abdomen erect showed multiple air fluid levels in small gut. USG Abdomen revealed dilated small bowel loops with probe tenderness in right iliac fossa. CECT abdomen showed conglomerate of small bowel loops with mesenteric vessels and mesenteric fat seen lying just anterior to the second part of the duodenum and posterior to the ileocaecal junction, middle colic vein, and superior mesenteric vessels. Diagnosis of Obstructed Right Para-duodenal Hernia was confirmed [Fig.4]. Patient was immediately taken for surgery.



**Figure 4:** CECT abdomen showing right paraduodenal hernia

Operative findings were consistent with right PDH. Approximately 3-4 feet of proximal small bowel loops were herniated through a mesenteric defect behind the superior mesenteric vessels in to the right mesocolon forming a sac. Small bowel loops were blue and very congested [Fig.5].



**Figure 5:** Right paraduodenal hernia sac with bowel loops

It was difficult to pull out the herniated bowel loops so we carefully opened the sac at an avascular area, and excised the sac. After confirming the viability, herniated loops were reduced. The defect was closed with continuous non-absorbable sutures taking care of superior mesenteric vessels. Post-operative period was uneventful and patient was discharged on forth day.

### Discussion

Internal hernia is a rare type of hernia, less than 1% of all abdominal hernias, in which abdominal contents herniates through a congenital or acquired defect in the peritoneal cavity. Internal hernias are classified into six types- 1. Paraduodenal hernias (50-55%), 2. Hernia through foramen of Winslow (6-10%), 3. Transmesenteric hernias (8-10%), 4. Pericaecal hernias (10-15%), 5. Intersigmoid hernias (4-8%), and 6. Paravesical hernias (<4%) [4].

PDH constitutes more than half of all internal hernias. Males are most commonly affected. Left PDH is three times more common than right PDH [1]. They occur due to malrotation of bowel during development and adhesions between mesocolon, mesentery and retroperitoneum. Left PDH occurs due to herniation of small bowel in Landzert's fossa situated to the left of ligament of Treitz and forth part of duodenum, posterior to inferior mesenteric vein and left mesocolon. In right PDH small bowel loops herniate in the fossa of Waldeyer's to the right of ligament of Treitz through a defect in first part of jejunal mesentery due to failure of fusion of mesentery to posterior parietal peritoneum[5].

Patients of PDH usually presents in 4<sup>th</sup> or 5<sup>th</sup> decade. Our cases presented in 2<sup>nd</sup> and 3<sup>rd</sup> decade respectively. Early diagnosis is probably due to liberal use of imaging modality like CECT. The symptoms of PDH are varied and nonspecific. Chronic intermittent abdominal pain is the commonest symptom which was present in both of our cases. Patients usually present with acute abdominal pain with features of intestinal obstruction, as in our cases [6].

Correct clinical diagnosis of PDH is very difficult because of varied presentation. Routine investigations are usually normal. Plain x-ray abdomen or contrast study may show few intestinal loops in left or right upper abdomen with features of intestinal obstruction.

Contrast enhanced abdominal CT is the gold standard for diagnosis of PDH. Typical findings in Left PDH include clumped intestinal loops in smooth encapsulated border (Donnelly's border) between stomach and pancreas, above and lateral to the forth part of duodenum, posterior to inferior mesenteric vein [3]. CECT abdomen in right PDH will show conglomerate of small bowel loops in smooth encapsulated border on right side just anterior to the second part of duodenum, posterior to middle colic vein

and superior mesenteric vessels. CECT also shows the viability and any compromise in the vascularity of herniated small bowel. Both of our cases were diagnosed correctly preoperatively by CECT.

Up to 50% cases with PDH may develop acute intestinal obstruction and its complications, hence surgery is always recommended in all cases of PDH [7]. Surgery can be done by open laparotomy or by minimally invasive laparoscopic method. Basic principle of surgery include reduction of the bowel loops from the hernia sac, checking the viability of bowel, resecting any nonviable segment, and repair of hernia defect.

Commonest method of repair of hernia defect is primary closure with continuous non-absorbable suture taking care not to injure inferior mesenteric vein in left PDH and Superior mesenteric vessels in right PDH [3]. Other method is wide opening of hernia orifice in avascular plane so that the hernia sac becomes part of general peritoneal cavity [3]. Excision of hernia sac has also been done but is not mandatory [6]. Recurrent PDH has been repaired with the use of mesh to close the defect [8].

In our first case, we reduced the viable small bowel loops from the hernia sac and did primary closure of defect using non absorbable suture safeguarding the inferior mesenteric vein. In the second case, reduction of bowel loops was difficult as they were tightly packed in the sac with bluish congested loops. We opened the sac in avascular portion right of the superior mesenteric vessels, reduced the bowel loops and excised the sac. Then the defect was closed with continuous nonabsorbable sutures to the right of superior mesenteric vessels and posterior parietal peritoneum.

In modern era, minimally invasive laparoscopic surgery is recommended in uncomplicated cases when there is no evidence of bowel ischemia or perforation in pre-operative CT scan. Laparoscopic repair is not advisable in complicated cases like gangrene or perforation of bowel, haemodynamic instability or significant adhesions [9,10].

### Conclusion:

Para-duodenal hernia should be kept in the differential diagnosis of acute intestinal obstruction, specially in virgin abdomen. In these cases CECT abdomen should be done at the earliest as it is the gold standard in pre-operative diagnosis. All cases should undergo surgery to prevent the complications. Laparoscopic surgery is feasible in uncomplicated cases, whereas open surgery is recommended in complicated cases or when laparoscopic expertise is not available.

## References

1. Kabbani D, Salem A, Holloway DK. Paraduodenal herniation: An internal herniation in a virgin abdomen. *Int J Surg Case Rep.* 2014;5(12):1148–1150. 25437660 doi:10.1016/j.ijscr.2014.11.021
2. Moussa MB, Nouhi I, Lachguar T, Absi ME, Alami EHEFE, Ouanani ME, Echarrab EM, Amraoui ME, Chkof MR. A paraduodenal hernia revealed by bowel obstruction: case report and literature review. *Pan Afr Med J.* 2018 Oct 17;31:120. doi: 10.11604/pamj.2018.31.120.13538. PMID: 31037180; PMCID: PMC6462366.
3. Gokal F, Akdamar F, Celenk Y, Akdemir Z. A case report of left paraduodenal hernia diagnosed preoperatively and treated laparoscopically. *Turk J Surg* 2018 34 (3): 243-246, doi: 10.5152/turkjsurg.2017.3322
4. John RJ, Ulahannan SE, Kurien JS, Joseph A, Kurien AS, Varghese SA, Thomas B, Varghese F. Rare Hernias Presenting as Acute Abdomen- A Case Series *jcdr* 2016 March;10(3):PR01-PR04. DOI: 10.7860/jcdr/2016/17356.7401 PMID: 27134943 PMCID: PMC4843328.
5. Shadhu, K., Ramlagun, D. & Ping, X. Para-duodenal hernia: a report of five cases and review of literature. *BMC Surg* 18, 32 (2018). <https://doi.org/10.1186/s12893-018-0365-8>
6. R. Downes, S.O. Cawich A case of a paraduodenal hernia *Int J Surg Case Rep*, 1 (2) (2010), pp. 19-21, 10.1016/j.ijscr.2010.06.003 PMID: 22096667; PubMed Central PMCID: PMC3199615]
7. Wakabayashi M, Kono S, Takahashi T, Laparoscopic repair of acute small bowel obstruction due to left paraduodenal hernia: A case report *Int J Surg Case Rep* 51 (2018) 194-199 PMID 30179801; doi: 10.1016/j.ijscr.2018.08.050
8. Palanivelu C, Rangarajan M, Jategaonkar PA, Anand NV, Senthilkumar K. Laparoscopic management of paraduodenal hernias: mesh and meshless repair. A report of four cases. *Hernia* 2008 Dec; 12(6): 649-53. PMID: 18465192 . Epub 2008 May 9. <https://doi.org/10.1007/s10029-008-0376-y>
9. Sleiman Y, El-Kheir A, El-Khoury M, Hamdach O, Ismail L, Allouch M. Small bowel obstruction secondary to left paraduodenal hernia: A case report and literature review. *Int J Surg Case Rep.* 53 (2018)29-31, <https://doi.org/10.1016/j.ijscr.2018.10.018>
10. Schizas D, Apostolou K, Krivan S, et al. Paraduodenal hernias: a systematic review of the literature. *Hernia* 23, 1187–1197 (2019). <https://doi.org/10.1007/s10029-019-01947-3>