

## COMPARATIVE STUDY IN BETWEEN INTRALESIONAL VITAMIN D3 AND INTRALESIONAL BLEOMYCIN IN THE TREATMENT OF CUTANEOUS VERRUCAE

Dr. Shrikant<sup>1</sup>, Dr. R.D. Mehta<sup>2</sup>, Dr. B.C. Ghiya<sup>3</sup>

<sup>1</sup>Resident Doctor, Department of Dermatology, Venereology and Leprosy, Sardar Patel Medical College, Bikaner, Rajasthan.

<sup>2</sup>Senior Professor, Department of Dermatology, Venereology and Leprosy, Sardar Patel Medical College, Bikaner, Rajasthan.

<sup>3</sup>Associate Professor, Department of Dermatology, Venereology and Leprosy, Sardar Patel Medical College, Bikaner, Rajasthan.

**Article Info:** Received 25 July 2020; Accepted 26 August 2020

**DOI:** <https://doi.org/10.32553/ijmbs.v4i8.1372>

**Corresponding author:** Dr. R.D. Mehta

**Conflict of interest:** No conflict of interest.

### Abstract

**Background:** Verruca is one of the common dermatopathologies which has multiple therapeutic options but with variable success rates, refractory cases and high recurrence rates. Nowadays, treatment with intralesional injections has gained recognition due to its effectiveness in clearing verrucae. These act by stimulating the cell-mediated immunity. Out of scores of options available for intralesional therapeutics, Vitamin D3 appears to be more promising but least evaluated. Therefore, we planned to evaluate the efficacy of intralesional Vitamin D3 in various types of cutaneous verrucae. Simultaneously the results were compared with intralesional bleomycin, also.

**Methods:** A total of 200 patients of cutaneous verrucae with varying size and duration were included in the experimental randomized comparative study. We divided them into two groups. Group A, comprising of 100 patients, received 0.2-0.5 ml intralesional Vitamin D3 (600,000 IU, 15mg/ml) and Group B, also of hundred subjects, received intralesional Bleomycin (1 mg/ml) into the base of verrucae. A maximum of 5 verrucae were injected per session at 3 weeks interval until resolution or for a maximum of 4 sessions. Patients were followed up for 6 months after the last injection to assess the clearance status and detect any recurrence.

**Results:** In Group A (Vitamin D3), 'Complete response', 'Partial response' and 'No response' were observed in 85.07%, 6.74% and 8.17% respectively after 4 sessions. Recurrence rate was 0.81% after 6 months. In Group B (Bleomycin), 'Complete response', 'Partial response' and 'No response' were found in 77.99%, 10.47% and 11.53% in the series. Recurrence rate was 1.71%, comparatively higher in group B.

**Conclusion:** The efficacy of intralesional Vitamin D3 was found significantly higher as compared to intralesional Bleomycin in the treatment of cutaneous verrucae with less recurrence rates. Vitamin D3 has an additional advantage of cost-effective treatment over Bleomycin. We purpose its use, as a primary mode of treatment in various types of cutaneous verrucae.

**Keywords:** Bleomycin, Vitamin D3, Verrucae.

### Introduction

Verrucae are the benign epidermal growths with focal extension of epithelial cells of skin and mucosa caused by human papillomavirus (HPV). It affects all age groups.<sup>[1]</sup> HPV has 200 phenotypes and 100 sequenced types as per genotyping.

There are numerous methods for treating the verrucae. But none, is labelled as gold standard treatment. It is very difficult to treat when these are numerous or present on unreachable sites.

Local destruction of verruca is the most commonly used modality; performed by electrocoagulation, chemical cautery, curettage, cryotherapy, laser therapy but these all require expensive equipments and can remove only the visible infected lesions, leaving the invisible infected tissue

behind resulting in higher chances of recurrence.<sup>[2]</sup> All these modalities may end with disfiguring scar marks.

In immunotherapy; the cell-mediated immunity stimulates, patient's immune system to eradicate HPV. Immunotherapy is cost-effective choice with high rate of resolution of both lesional and distant sites (lesions at different anatomical sites, away from injected one) with minimal side effects.<sup>[1]</sup>

Different types of immune stimulants are available, e.g. pro inflammatory cytokines like interferons and interleukin(IL)-2; intralesional antigens like purified protein derivative; *Candida* and *Trichophyton*; vaccines like the mumps, measles, and rubella (MMR) vaccine; *Mycobacterium w* and *Bacillus Calmette-Guerin* (BCG) vaccine; topical contact sensitizers like diphencyclopropenone and dibutyl ester; and immune enhancers like zinc sulfate.<sup>[2]</sup>

Vitamin D has the property to regulate the epidermal proliferation and cytokine production and, when used as an intralesional injection, it acts as an immunotherapeutic agent.<sup>[3]</sup>

It has immunomodulatory effects by inhibiting the expression of interleukin-6(IL-6), IL-8, TNF-alpha-gamma, mediated by VDR-dependent pathway. Activation of Toll-like receptor (TLR) of human macrophages upregulates the expression of Vitamin D receptor and Vitamin D1-hydroxylase genes, leading to induction of the antimicrobial peptide.<sup>[4]</sup>

Another modality for treatment of verruca is intralesional bleomycin which is a glycopeptide derived from *Streptomyces verticillus*. It is antimitotic, antibacterial and antiviral agent which acts by binding with deoxyribonucleic acid (DNA). Intralesional bleomycin has been found to be very effective in periungual and palmoplantar verrucae.<sup>[5-6]</sup>

The prospective study was undertaken, to evaluate the efficacy of intralesional Vitamin D3 in various types of cutaneous verrucae. Simultaneously the results were compared with intralesional bleomycin.

#### Materials and Methods

An experimental randomized comparative study was conducted on 200 patients of cutaneous verrucae, attending the outpatient department from July 2018 to June 2019. This study was approved by the Institutional Ethics & Research Board of our institute. An informed written consent was obtained from all the patients, as per institutional regulation prior to initiation of the treatment. Cases were diagnosed on the basis of typical clinical manifestation; Alternate patients were allocated by simple randomization method to group A and B. Group A received intralesional Vitamin D3 and group B received intralesional Bleomycin.

The characteristics of the verrucae for each patient such as, type, size, number, duration, presence or absence of side effects and photographs were recorded at the start of the study and at each follow-up visit. Three weeks washout period was allowed if the patients were still on any therapy before coming to the out patient department. They were also instructed not to use any other verruca therapies during the course of the study.

Patients were included, who had extra genital verrucae and above the age of 18 years. Patients who were on immunosuppressive drugs and had systemic illness, history of peripheral vascular disease; the pregnant and lactating females were excluded from study.

#### Method of administration of Vitamin D3 and Bleomycin-

**Schedule:** In both the groups; A maximum of 5 verrucae were injected per session. The injections were repeated at

3 weekly intervals until complete resolution or for a total 4 sessions, at the most.

Group A: Using a 26-gauge needle insulin syringe with bevel upward, 0.2 to 0.5ml vitamin D3 solution (600,000 IU; 15mg/ml) was slowly injected in base of verruca.

Group B: Bleomycin for injection is available as 15 mg powder in a vial. It was formulated first with 5ml distilled water. This stock solution could be stored for 60 days, at 4-8°C. Before injecting, it was further diluted by adding mixture of 20 mg/mL (2%) lidocaine and 0.0125mg/ml epinephrine, double the amount taken from the vial, so that concentration becomes 1 mg/ml or 1 unit/ml (0.1% or 1 U/ml) ready to be used. This was injected at the base of verrucae, using a unit insulin syringe. Injection was continued until verruca blanches.

After 3 weeks of injections, a black, ecchymosed eschar developed which was pared, and residual verrucae if present were injected again. After each injection antibiotics and anti-inflammatory agents were prescribed for 5 days to prevent superadded bacterial infection and post injection pain. Patients were followed up on 21st day of injection till 6 months after the last injection to detect any recurrence.

The response status on the basis of decrease in verruca size was created. The response rate is classified as follows:

1. COMPLETE RESPONSE (CR) -If all verrucae showed complete or 100% disappearance.
2. PARTIAL RESPONSE (PR) - If some verrucae show decrease in size and the number is more than 50% but less than 100% as compared to the pre-procedural status.
3. NO RESPONSE (NR)- If some verrucae improve in size but the number is less than 50% as compared to the pre-procedural status.

Chi square statistical test were applied to analyse the results, 'p values' less than 0.05 were consider statistically significant.

#### Results:

Present study was conducted on 200 fresh cases with a total of 956 cutaneous verrucae.

Following observations were made during the study:

Most of the patients were in age group of 18-30 years. Cutaneous verrucae were more common in males with male: female ratio of 1.32:1.

Result in both the groups were evaluated at three weeks interval. Response of Intralesional Vitamin D3 in Cutaneous verrucae are tabulated in table 1.

**Table 1:** Response rates of cutaneous verrucae with Intralesional Vitamin D3

Type of Verrucae	Complete Response (CR)					Partial Response (PR)	No Response (NR)	Total
	IL-1 (n)	IL-2 (n)	IL-3 (n)	IL-4 (n)	Total (n)			
Common Verrucae	120 (83.33%)	06 (4.16%)	05 (3.47%)	03 (2.08%)	134 (93.05%)	04 (2.77%)	06 (4.16%)	144
Plantar Verrucae	89 (84.76%)	03 (2.85%)	02 (1.90%)	02 (1.90%)	96 (91.42%)	05 (4.76%)	04 (3.80%)	105
Palmar Verrucae	77 (84.61%)	03 (3.29%)	02 (2.19%)	01 (1.09%)	83 (91.20%)	03 (3.29%)	05 (5.49%)	91
Filiform Verrucae	38 (66.66%)	02 (3.50%)	02 (3.50%)	02 (3.50%)	44 (77.19%)	05 (8.77%)	08 (14.03%)	57
Verruca Plana	36 (44.44%)	06 (7.40%)	04 (4.93%)	04 (4.93%)	50 (61.72%)	15 (18.51%)	16 (19.75%)	81
Periungual Verrucae	06 (54.54%)	01 (9.09%)	01 (9.09%)	01 (9.09%)	09 (81.81%)	01 (9.09%)	01 (9.09%)	11
Total	366 (74.84%)	21 (4.29%)	16 (3.27%)	13 (2.65%)	416 (85.07%)	33 (6.74%)	40 (8.17%)	489

The abbreviations in the tables stands as;

IL-1; Post intralesional at 3 weeks

IL-2; Post intralesional at 6 weeks

IL-3; Post intralesional at 9 weeks

IL-4; Post intralesional at 12 weeks

PR & NR; After 12 weeks n; Number of cases

**Table 2:** Response of Intralesional Bleomycin in Cutaneous verrucae

Type of Verrucae	Complete Response (CR)					Partial Response (PR)	No Response (NR)	Total
	IL-1 (n)	IL-2 (n)	IL-3 (n)	IL-4 (n)	Total (n)			
Common Verrucae	100 (74.07%)	10 (7.40%)	06 (4.44%)	04 (2.96%)	120 (88.88%)	05 (3.70%)	10 (7.40%)	135
Plantar Verrucae	81 (82.65%)	04 (4.08%)	03 (3.06%)	01 (1.02%)	89 (90.81%)	04 (4.08%)	05 (5.10%)	98
Palmar Verrucae	74 (82.22%)	02 (2.22%)	02 (2.22%)	01 (1.11%)	79 (87.77%)	06 (6.66%)	05 (5.55%)	90
Filiform Verrucae	36 (66.66%)	02 (3.70%)	02 (3.70%)	01 (1.85%)	41 (75.92%)	07 (12.96%)	06 (11.11%)	54
Verruca Plana	16 (20%)	06 (7.50%)	03 (3.75%)	02 (2.50%)	27 (33.75%)	26 (32.50%)	27 (33.75%)	80
Periungual Verrucae	06 (54.54%)	01 (9.09%)	01 (9.09%)	01 (9.09%)	09 (81.81%)	01 (9.09%)	01 (9.09%)	11
Total	313 (66.88%)	25 (5.34%)	17 (3.63%)	10 (2.13%)	365 (77.99%)	49 (10.47%)	54 (11.53%)	468

**Table 2:** Response rates of cutaneous verrucae with Intralesional Bleomycin

Difference in the response of number of verrucae in both Bleomycin and Vitamin D3 groups showed statistically significant difference ( $p < 0.05$ ).

In Group A, overall verrucae of different morphology showed 75 % complete response after a single injection. Additional 10% verrucae showed complete response after 2<sup>nd</sup>, 3<sup>rd</sup> and 4<sup>th</sup> injection as depicted in table 1. Group B showed 67% complete response in different morphology variants after a single injection. Additional 11% verrucae had complete response after 2<sup>nd</sup>, 3<sup>rd</sup> and 4<sup>th</sup> injection as depicted in table 2.

Group A 7% patients had 'Partial response' and 8% showed 'No response'. Whereas in group B 10% subject had 'Partial response' and 12 % were in category of, 'No response'.

**Table 3:** Response of Intralesional Vitamin D3 in combination of different types of Cutaneous Verrucae

Type of Verrucae	Complete Response (CR)					Partial Response (PR)	No Response (NR)	Total
	IL-1 (n)	IL-2 (n)	IL-3 (n)	IL-4 (n)	Total (n)			
Palmo-Plantar Verrucae	30 (93.75%)	00	02 (7.25%)	00	32 (100%)	00	00	32
Periungual-Plantar Verrucae	09 (100%)	00	00	00	09 (100%)	00	00	09
Periungual-Common Verrucae	05 (100%)	00	00	00	05 (100%)	00	00	05
Periungual- Palmar Verrucae	05 (100%)	00	00	00	05 (100%)	00	00	05
Filiform-Common Verrucae	07 (46.66%)	00	00	00	07 (46.66%)	05 (33.33%)	03 (20%)	15
Palmar-Common Verrucae	07 (66.67%)	00	00	00	07 (66.67%)	00	02 (33.33%)	09
Total	63 (84.33%)	00	02 (2.67%)	00	65 (86.67%)	05 (6.67%)	05 (6.67%)	75

**Table 3:** Response distribution amongst various combinations of verrucae in Group A**Table 4:** Response of Intralesional Bleomycin in combination of different types of Cutaneous Verrucae

Type of Verrucae	, Complete Response (CR)					Partial Response (PR)	No Response (NR)	Total
	IL-1 (n)	IL-2 (n)	IL-3 (n)	IL-4 (n)	Total (n)			
Palmo-Plantar Verrucae	23 (60.52%)	06 (15.78%)	02 (5.26%)	00	31 (81.47%)	04 (10.52%)	03 (7.89%)	38
Periungual-Plantar Verrucae	03 (100%)	00	00	00	03 (100%)	00	00	03
Periungual-Common Verrucae	05 (100%)	00	00	00	05 (100%)	00	00	05
Periungual-Palmar Verrucae	04 (66.67%)	00	00	01(16.66%)	05 (83.33%)	01 16.66%	00	06
Filiform-Common Verrucae	07 (46.66%)	00	00	00	07 (46.66%)	02 (13.33%)	06 (40%)	15
Palmar-Common Verrucae	05 (100%)	00	00	00	05 (100%)	00	00	05
Total	47 (65.27%)	06 (8.33%)	02 (2.77%)	01 (1.38%)	56 (77.78%)	07 (9.72%)	09 (12.50%)	72

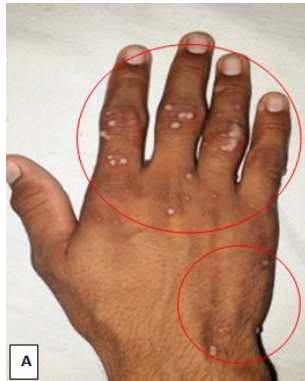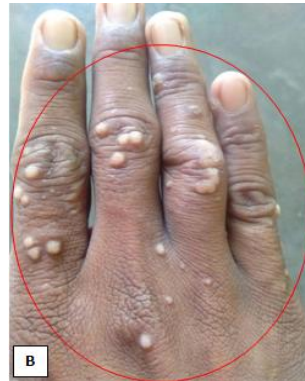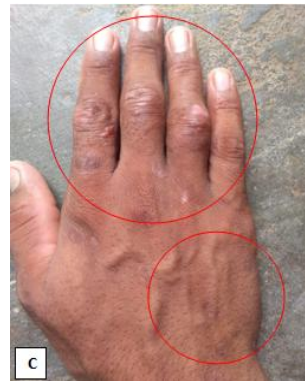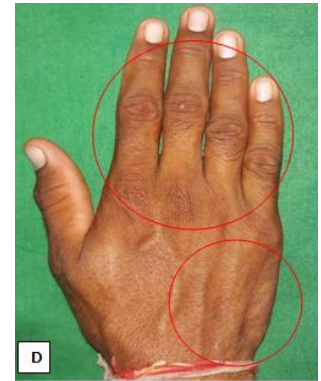
Table 4: Response analysis amongst Group B patients with different verrucae in combination

Difference in the response in combination of different types of verrucae in both Bleomycin and Vitamin D3 groups showed statistically significant difference ( $p < 0.05$ ).

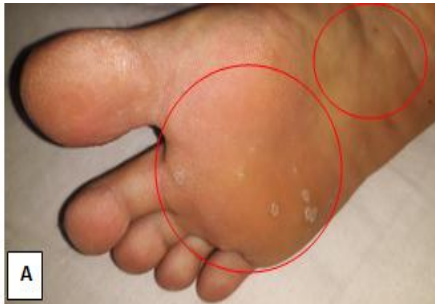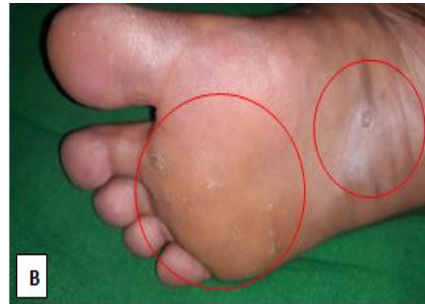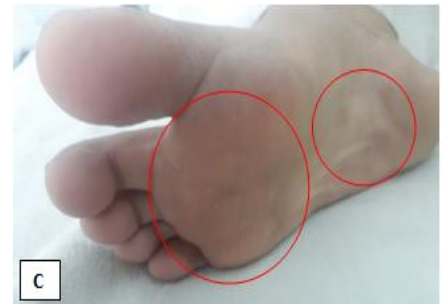Group A showed 87 % complete response after a single injection. Group B showed 78% complete response after a single injection. Group A patients showed 5%, 'Partial response' and 5% 'No response'. Beside that subjects in group B showed 10%, 'Partial response' and 12 % had 'No response'.

Patients in both the groups felt pain during intralesional procedure and the pain persisted for few days. In group A patients felt swollen sites, pruritus which was within tolerable limits and none of them required any interventional medication for the adverse reaction. None Of the patients complained any systemic adverse event.

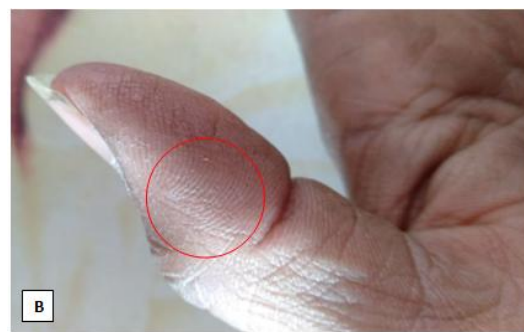### Group A (Vitamin D3)

Fig A-1<sup>st</sup> visit: Week 0Fig B- 2<sup>nd</sup> visit: Week 3Fig C- 3<sup>rd</sup> Visit: Week 6Fig D- 4<sup>th</sup> Visit: Week 9 Complete

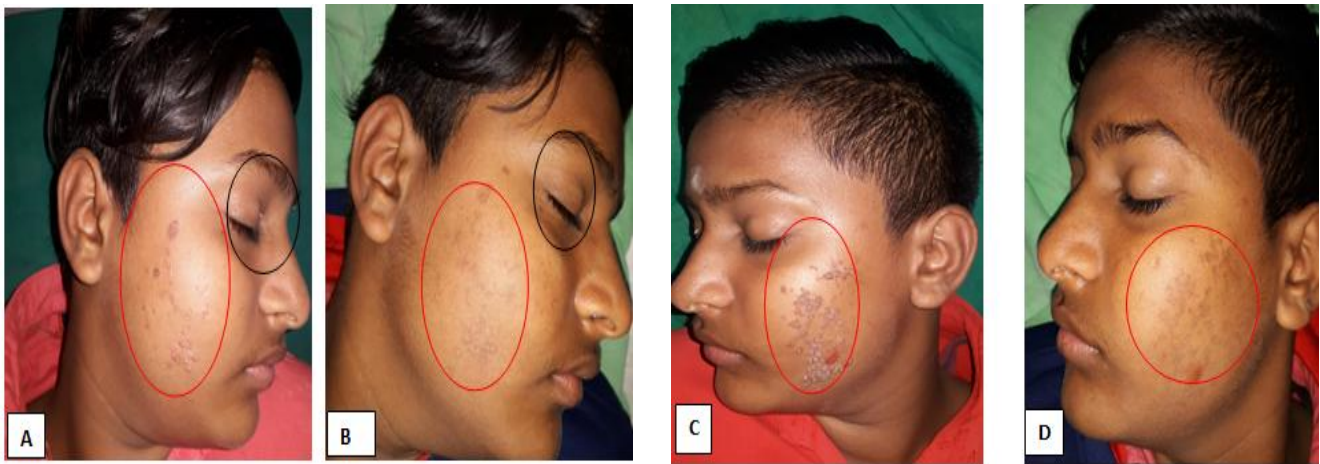#### 1. VERRUCA VULGARIS

Fig A- 1<sup>st</sup> Visit: Week 0Fig B- 2<sup>nd</sup> Visit: Week 3Fig C- 3<sup>rd</sup> Visit: Week 6, Complete Response

#### 2. PLANTAR VERRUCAE

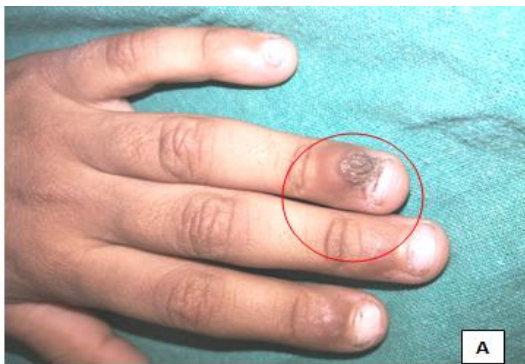Fig A- 1<sup>st</sup> Visit: Week 0Fig B- 2<sup>nd</sup> visit: Week 3, Complete

#### 3. PALMAR VERRUCAE

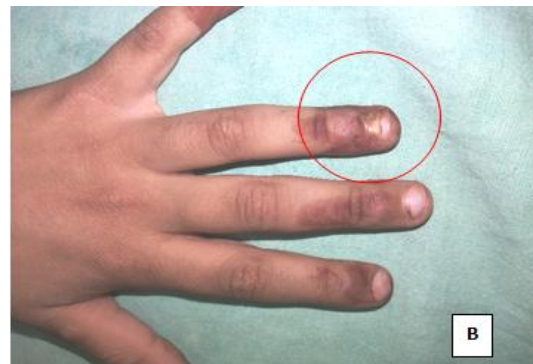

**Fig. A-1<sup>st</sup> Visit: Week 0; Red circle- Plain verrucae & Black circle Filiform verrucae, Fig. B- 3<sup>rd</sup> Visit: Week 6- Complete Response in both circle, Fig C – 1<sup>st</sup> Visit: Week 0; Fig D- 3<sup>rd</sup> Visit: Week 6- Complete Response**

#### 4. FILIFORM VERRUCAE & VERRUCA PLANA

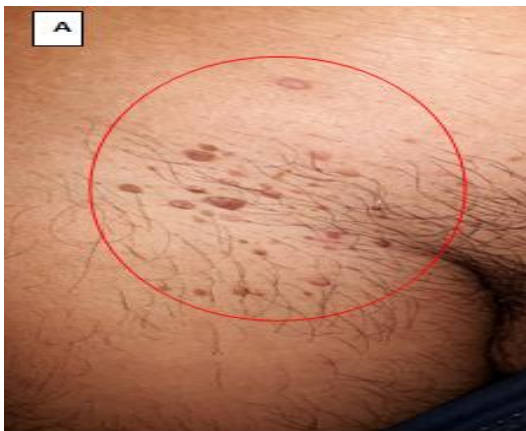

**Fig A- 1<sup>st</sup> Visit: Week 0,**

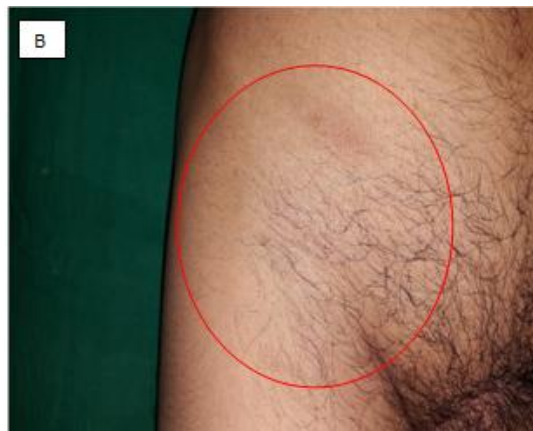

**Fig B- 2<sup>nd</sup> Visit: Week 3**

#### 5. PERIUNGUAL VERRUCAE



**Fig A-1<sup>st</sup> Visit: Week,**



**Fig B-2<sup>nd</sup> Visit: Week 3, Complete Response**

#### 6. VERRUCA VULGARIS

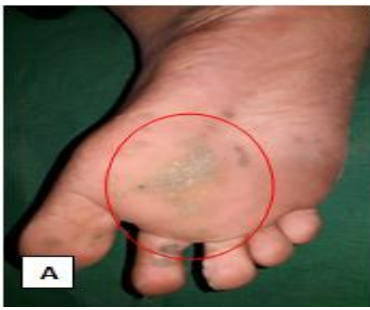

Fig A- 1<sup>st</sup> Visit: Week 0,

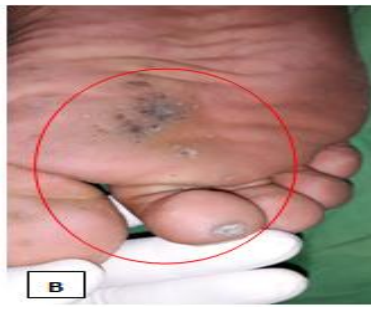

Fig B- 2<sup>nd</sup> Visit: Week 3, Black Eschar,

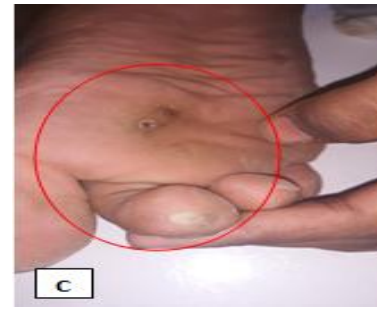

Fig C- 3<sup>rd</sup> Visit: Week 6, Complete Response

### 7. PLANTAR VERRUCAE



Fig A- 1<sup>st</sup> Visit: Week 0,

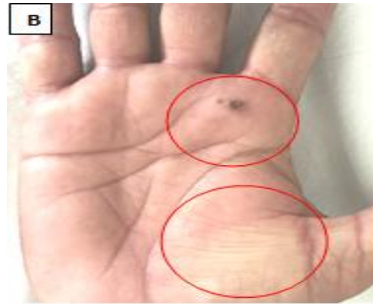

Fig B- 2<sup>nd</sup> Visit: Week 3,

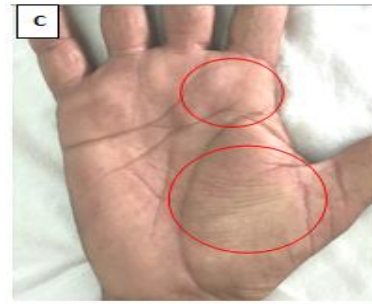


Fig C- 3<sup>rd</sup> Visit: Week 6, Complete Response

### 8. PALMAR VERRUCAE

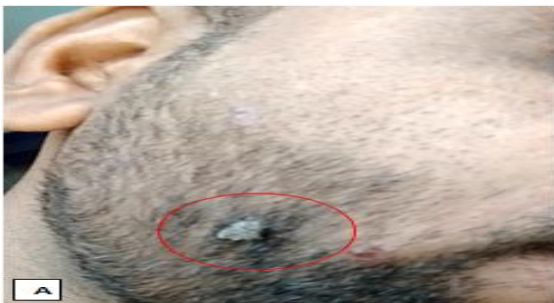

Fig A -1<sup>st</sup> Visit: Week 0,

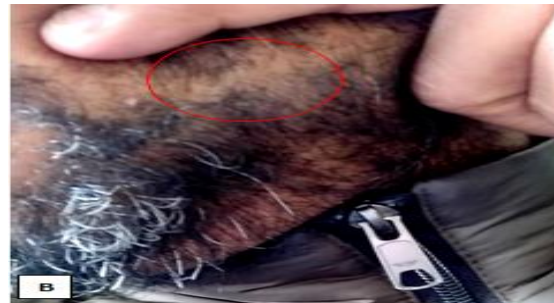

Fig B- 2<sup>nd</sup> Visit: Week 3, Complete Response

### 9. FILIFORM VERRUCAE

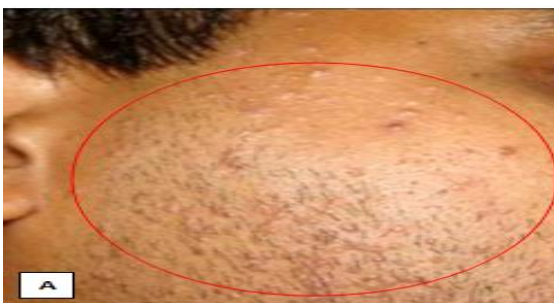

Fig A- 1<sup>st</sup> Visit: Week 0,

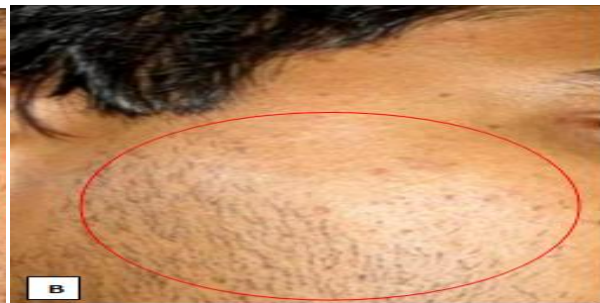

Fig B- 2<sup>nd</sup> Visit: Week 12, Complete and Partial Response

### 10. VERRUCA PLANA

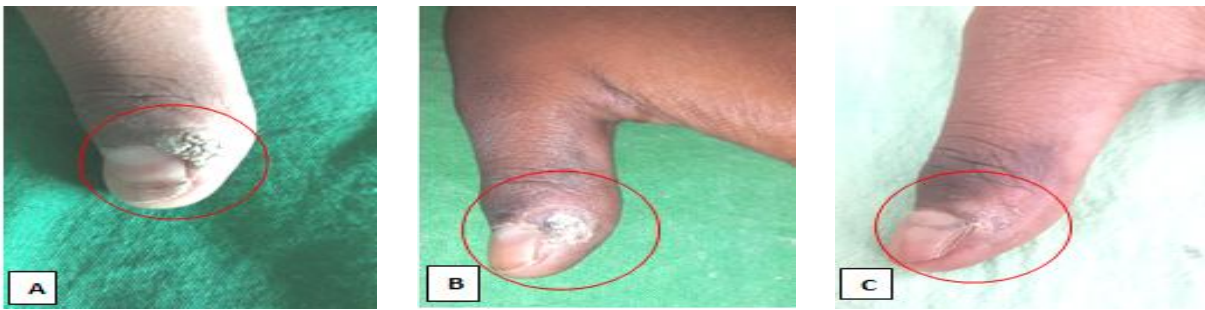

Fig A- 1<sup>st</sup> Visit: Week 0, Fig B- 2<sup>nd</sup> Visit: Week 3, Black eschar formed after injection, Fig C- 3<sup>rd</sup> Visit: Week 6, Complete Response with P.I.H.

## 11. PERIUNGUAL VERRUCAE

### Discussion

In the present study, bleomycin solution was injected into the verruca using a unit insulin syringe. Multiple techniques have been used to deliver bleomycin to the verrucae in other studies. Agius et al observed<sup>[7]</sup> complete or partial clearance in 89.9% recalcitrant plantar verrucae after one to five sessions of bleomycin injections using dermojet. The present study showed similar cure rate as the above-mentioned studies suggesting that the various techniques are equally effective in delivering bleomycin into the lesion.

None of the patients had serious side effects including scarring, change in pigmentation, nail damage or Raynaud's phenomenon in our study. The only side effect noted was pain at the site of injection during the procedure which varied in intensity according to the perception of the patients from mild to severe.

After a follow-up of 6 months, recurrence rate of 1.71%, was found in the present study, while Aguis et al reported a recurrence rate<sup>[7]</sup> of 4.4% on using dermojet. We used intralesional Vitamin D3, which is relatively new treatment option for verrucae; as immune.

Aktas et al, used intralesional Vitamin D3 for plantar verrucae. Twenty patients were included in thier study, and 7.5 mg of Vitamin D3 injection was given at monthly interval for a maximum of 2 sessions. They reported<sup>[3]</sup> complete clearance in 80% of patients while one patient had partial response and 3 failed to show any response at the end of 8 weeks. The complete response of plantar verrucae observed in our study was 91.42% which is quite high as compared to above mentioned study, by Aktas et al.

Raghu Kumar et al, on 64 patients having recalcitrant verrucae (i.e. showing no response to conventional therapies)<sup>[8]</sup> gave intralesional vitamin D3. 'Complete response' was seen in 54 of 60 (90%) of the patients, 'Partial response' in 4 of 60 (6.66%), and 'No response' in 2 of 60 (3.33%). In our study the sample size was quite large

than above the mentioned study and our study design was comparative, one.

Kavya, et al used intralesional Vitamin D3 for various cutaneous verrucae,<sup>[9]</sup> observed Complete clearance in 19 (82.60%) out of 23 patients. Six patients (14.28%) showed moderate response and three patients (7.14%) had mild response. The complete response in plantar verrucae group was observed in our study, 91.42% patients and in common verrucae, it was 93.05% which is quite high as compared to above mentioned study.

In our study we compared safety and efficacy of intralesional Vitamin D3 and bleomycin in cutaneous verrucae. It is unique comparative study conducted for the first time as per scanning of the literature to best of our efforts. In the present study, a total of 489 verrucae were treated with intralesional Vitamin D3 and complete response, partial response and no response after 4 sessions were observed in 85.07%, 6.74% and 8.17% of each category. Intralesional bleomycin was given in 468 verrucae and complete response, partial response and no response after 4 sessions were observed in 77.99%, 10.47% and 11.53% respectively. Recurrence rate of 0.81% was seen in Vitamin D3 group and 1.71% in bleomycin group.

The difference in response of two groups is statistically significant ( $p < 0.05$ ) proving that intralesional Vitamin D3 is more effective than intralesional bleomycin in treatment of cutaneous verrucae. Patients in both the groups felt pain during intralesional procedure and the pain persisted for few days. Injection Vitamin D3 costs too lower than Injection Bleomycin.

Therefore, from above discussion we propose the use of intralesional Vitamin D3 in the treatment of cutaneous verrucae because it is safe, inexpensive and more effective.

### Conclusion

This study proves that both intralesional Vitamin D3 and intralesional Bleomycin are highly effective and safe for the

treatment of cutaneous verrucae which usually do not respond to other modalities of treatment. Both the drugs have the potential to become first line therapy in the treatment of cutaneous verrucae.

The efficacy of intralesional Vitamin D3 was found significantly higher as compared to intralesional Bleomycin in the treatment of cutaneous verrucae. Vitamin D3 has an additional advantage of cost-effective treatment over Bleomycin and we suggest its use, as a primary mode of treatment in all cases of cutaneous verrucae.

#### References

1. Androphy EJ & Lowry DR. Verrucae. In Wolff K, Goldsmith LA, Katz SI, et al editors. Fitzpatrick's Dermatology in General Medicine. 7th ed. New York: McGraw Hill Publishing; 2008.p.1914-22.
2. Lipke MM. An armamentarium of verruca treatments. Clin Med Res. 2006;4:273-293.
3. Aktas H, Ergin C, Demir B, et al. Intralesional vitamin D injection may be an effective treatment option for verrucae. J Cutan Med Surg. 2016; 20:118-122.
4. Liu PT, Stenger S, Li H, Wenzel L, Tan BH & Krutzik SR. Toll-like receptor triggering of a vitamin D-mediated human antimicrobial response. Science.2006; 311:1770-1773.
5. Shumer SM & O'Keefe EJ. Bleomycin in the treatment of recalcitrant verrucae. J Am Acad Dermatol 1983; 9:91-6. 11.
6. Bunney MH, Nolan MW, Buxton PK, Going SM & Prescott RJ. The Treatment of resistant verrucae with intralesional bleomycin: A controlled clinical trial. Br J Dermatol. 1984; 110:197-207.
7. Aguis E, Mooney JM, Bezzina AC & Yu RC. Dermojet delivery of bleomycin for the treatment of recalcitrant plantar verrucae. J Dermatolog Treat 2006;17:112-6.
8. Raghukumar S, Ravikumar BC, Vinay KN, Suresh MR, Aggarwal A & Yashovardhana DP. Intralesional Vitamin D3 injection in the treatment of recalcitrant verrucae: a novel proposition. J Cutan Med Surg 2017 Jul;21(4):320-4.
9. Kavya M, Shashikumar BM, Harish MR & Shweta BP. Safety and efficacy of intralesional Vitamin D3 in cutaneous verrucae: An open uncontrolled trial. J Cutan Aesthet Surg 2017; 10:90-4.