

# PARS PLANA VITRECTOMY IN POST-CATARACT SURGERY ENDOPHTHALMITIS IN CIPTO MANGUNKUSOMO HOSPITAL

Fitria Romadiana<sup>1</sup>, Ari Djatikusumo<sup>1</sup>, Elvioza<sup>1</sup>, Gitalisa Andayani Adriono<sup>1</sup>, Anggun Rama Yudantha<sup>1</sup>, Mario Marbungaran Hutapea<sup>1</sup>, Andi Arus Victor<sup>1\*</sup>

<sup>1</sup>Department of Ophthalmology, Faculty of Medicine, Universitas Indonesia

Cipto Mangunkusumo Hospital, Jakarta

**Article Info:** Received 11 September 2020; Accepted 18 October 2020

**DOI:** <https://doi.org/10.32553/ijmbs.v4i10.1448>

**Corresponding author:** Andi Arus Victor

**Conflict of interest:** No conflict of interest.

## Abstract

**Background:** Endophthalmitis is one of the emergencies in ophthalmology and can cause blindness. The most common cause of endophthalmitis in intraocular surgery is cataract surgery. Immediate diagnosis and treatment can provide optimal final vision. This research aimed to describe the demographic data, and causative microorganisms, as well as the success rate of visual outcome after pars plana vitrectomy (PPV) in post-cataract surgery endophthalmitis in Cipto Mangunkusumo Hospital.

**Methods:** A retrospective descriptive study of post-cataract surgery endophthalmitis underwent vitrectomy in Cipto Mangunkusumo Hospital, Indonesia, from January 2017 - June 2017.

**Results:** There were twenty one cases of post-cataract surgery endophthalmitis undergoes PPV within the period of January 2017-June 2017. The most frequently identified causative microorganism was Staphylococcus (23%). There was an improvement of visual acuity after PPV procedure in 47,6% post-cataract surgery endophthalmitis.

**Conclusion:** Immediate PPV is an effective treatment and leads to vision improvement in post-cataract surgery endophthalmitis.

**Keywords:** pars plana vitrectomy, endophthalmitis, cataract surgery

## Introduction

Endophthalmitis is an emergency that can cause blindness and requires immediate treatment to get better final visual acuity. The most common cause of exogene endophthalmitis is intraocular surgery, especially cataract surgery, which is about 90% of all cases of post-operative endophthalmitis. Although the incidence of post-cataract surgery endophthalmitis showed significant changes over time, Hesam et al.<sup>2</sup> reported that the incidence of post-cataract surgery endophthalmitis varied between 0.04% - 0.2%. Other study suggests that post-cataract surgery endophthalmitis has increased in the last two decades from 0.09% in the 1990 to 0.27% in the 2000. This increase is due to the increasing number of cataract surgeries in the world.<sup>1</sup>

Pars Plana vitrectomy (PPV) in endophthalmitis aims to remove infectious material and vitreous debris so that it can eliminate the infection quickly.<sup>2</sup> PPV can immediately improve final vision and prognosis. Endophthalmitis Vitrectomy Study (EVS) found that cases with initial VA of light perception (LP) had improve final VA of 20/40 or better, and can reduce the poor final visual outcome by 50%.<sup>5</sup>

This research aims to describe the demographic data, clinical characteristics, causative microorganisms and

visual outcomes after PPV in post-cataract surgery endophthalmitis in Cipto Mangunkusumo Hospital.

## Method

This is a retrospective descriptive study of post-cataract surgery endophthalmitis patients in Cipto Mangunkusumo Hospital, Indonesia, who underwent PPV from January 2017 until December 2017. The data was collected from post-cataract surgery endophthalmitis patient's medical records. The collected data, including demographic data, treatment methods, causative organisms, functional outcomes, and factors associated with improved visual outcomes, were retrospectively reviewed. The exclusion criteria were all other causes of endophthalmitis and patients with incomplete medical records. The patients were classified as "improved" visual outcomes when their final best-corrected visual acuity (BCVA) was better than initial BCVA. The collected data were then processed descriptively, and all variables presented in the table and graphic.

## Results

Based on medical record data, there were twenty one post-cataract surgery endophthalmitis cases who underwent PPV in the period of January 2017 - December 2017.

**Table 1:** Patient's Demographic

| Variable                  | Frequency | Percentage (%) |
|---------------------------|-----------|----------------|
| <b>Age (n = 21)</b>       |           |                |
| 40 - < 60 years old       | 10        | 47.6           |
| >60 years old             | 11        | 52.4           |
| <b>Initial VA (n= 21)</b> |           |                |
| NLP                       | 1         | 4.7            |
| LP                        | 4         | 19.0           |
| 1/300                     | 13        | 61.9           |
| ≥ 1/60                    | 3         | 14.2           |
| <b>Onset (n = 21)</b>     |           |                |
| ≤ 7 days                  | 12        | 57.1           |
| > 7 days                  | 9         | 42.9           |

In table 1, the majority of post-cataract surgery endophthalmitis patients have initial visual acuity (VA) ≤ 1/300 (85.7%) and the onset of cases occurred within ≤7 days (52.4%).

**Table 2:** Treatment Modalities and Retinal Condition

| Variable  | Frequency | Percentage (%) |
|---|-----------|----------------|
| <b>Procedure Type (n = 21)</b>                      |           |                |
| Vx + AB intravitreal                                | 17        | 81             |
| Vx + AB intravitreal + SO                           | 2         | 9.5            |
| Vx + AB intravitreal + EL + Triamcinolone Acetonide | 2         | 9.5            |
| <b>PPV Period (n = 21)</b>                          |           |                |
| < 24 hours  | 9         | 42.9           |
| 24 hours – < 72 hours                               | 7         | 33.3           |
| ≥3 hours  | 5         | 23.8           |
| <b>Retinal Condition (n = 21)</b>                   |           |                |
| Retinal Necrosis                                    | 9         | 42.9           |
| Retinal Detachment                                  | 12        | 57.1           |

Vx: vitrectomy; AB: vancomycin 0,1 cc + ceftazidime 0,1 cc; EL: endolaser; SO: silicone oil

Table 2 summarized the treatment modalities and retinal condition. It describes that all cases were underwent vitrectomy and given intravitreal antibiotic injection. There were 9 (42.9%) cases of retinal necrosis and 12 (57.1%) cases of retinal detachment found upon PPV procedure.

**Table 3:** Summary of Culture Result

| Variable                            | Frequency | Percentage (%) |
|-------------------------------------|-----------|----------------|
| (n:16, no data:5)                   |           |                |
| <i>Staphylococcus epidermidis</i>   | 3         | 16.7           |
| <i>Staphylococcus Saprophyticus</i> | 1         | 6.3            |
| <i>Candida Albicans</i>             | 1         | 6.3            |
| <i>Bacillus Sp</i>                  | 1         | 6.3            |
| <i>Pseudomonas aeruginosa</i>       | 1         | 6.3            |
| <i>Aspergillus flavus</i>           | 1         | 6.3            |
| Negative Culture                    | 8         | 50             |

Table 3 shows the results of culture is found *Staphylococcus* (23%). *Candida albicans*, *Bacillus sp*, *Pseudomonas aeruginosa*, and *Aspergillus flavus* were each found in 1 subject (6.3%).

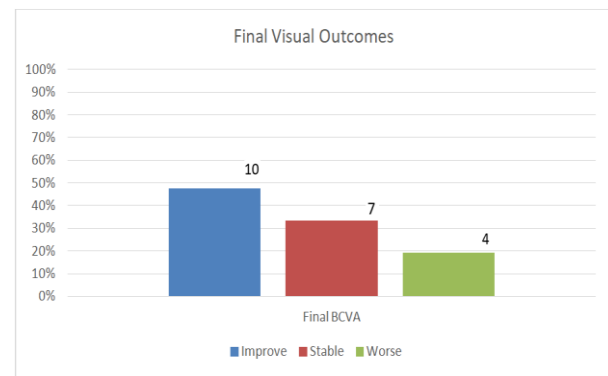
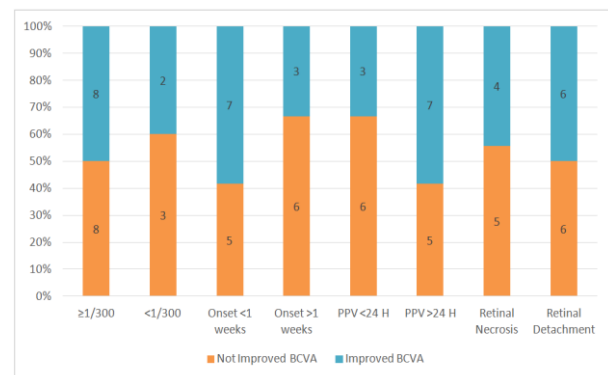
**Figure 1:** Functional Visual Outcomes after Vitrectomy

Figure 1 shows that as many as 10 (47.6%) cases had increased final BCVA, 7 (33.3%) cases were stable, and only 4 (19.1%) cases had worse final VA after PPV surgery.

**Figure 2:** Frequency of Visual Acuity Improvement Based on Initial Visual Acuity, Onset, PPV Period, and Retinal Condition

Factors associated with visual outcomes were demonstrated in figure 2. It revealed that cases with presenting VA better than 1/300 could get better final vision after PPV procedure (50%). Cases with retinal detachment also showed an improvement in final VA after vitrectomy (50%). The onset and time of surgery could affect the visual outcome after vitrectomy.

## Discussion

Acute endophthalmitis is a rare complication after cataract surgery, but it is an emergency in ophthalmology because it can cause blindness.<sup>3</sup> The incidence of post-cataract surgery endophthalmitis ranges from 0.03% -0.2%.<sup>9,12</sup> Research by Jeong *et al.*<sup>14</sup> reported the incidence of endophthalmitis after cataract surgery of 0.02% -0.08%. The increased incidence is due to an increase number of cataract cases that make cataract surgery the most commonly performed surgery worldwide.<sup>3</sup> The age range of post-cataract surgery endophthalmitis in this study was predominantly >60 years old (52.4%). Based on a study by Torabi *et al.*<sup>8</sup>, it was found that the average age of post-cataract surgery endophthalmitis patients were 68.7 years

old. Other study reported the age of patients at diagnosis ranged between 56-84 years old.<sup>12</sup> Age over 50 years old is a factor associated with poor outcomes in final VA.<sup>13</sup>

Cases with presenting visual acuity better than light perception (LP) is a significant factor for achieving better final visual acuity.<sup>10</sup> In this study, it was found that cases with initial VA better than 1/300 could get improvement in final VA by 50%, while cases with initial VA worse than 1/300 only 2 out of 5 cases (40%) had better final vision. Jeong *et al.*<sup>13</sup> reported 52.4% cases have initial VA of 1/300 and 15.2% with initial VA of LP. The results of the regression analysis of the research found that poor initial visual acuity was a significantly related factor to poor visual outcome after PPV (odds ratio (OR): 1,114; 95% confidence interval (CI): 1,090-1,336; P = 0.004). According to study conducted by EVS, the initial VA of LP was a risk factor for the decrease of final visual acuity.<sup>12</sup>

In this study, all cases (100%) were underwent PPV surgery and given intravitreal antibiotic injection. The use of intravitreal antibiotics aims to distribute antibiotics into the vitreous cavity.<sup>5</sup> Although EVS reported that immediate vitrectomy in endophthalmitis was only useful in cases with initial VA worse than LP, several recent studies have reported the benefits of immediate vitrectomy in cases of post-cataract surgery endophthalmitis.<sup>5,13,14,15</sup> In addition, Jeong *et al.*<sup>14</sup> reported that patients who only received intravitreal antibiotic injections more often required more procedure than those who had prompt vitrectomy. Another factor affecting the improve of final vision is the time interval from onset to vitrectomy surgery.<sup>13</sup> PPV performed within <24 hours contributes to better visual acuity outcomes because it can immediately remove the infectious microorganisms thereby reducing the number of inflammatory cells.<sup>13</sup> According to this study, PPV performed within <24 hours had better final visual acuity by 66.7%.

Microorganisms on the eye surface can contaminate the aqueous humor in 7-43% of cataract surgery cases. During cataract surgery, the posterior lens capsule should remain intact, but if there is a leak, it can increase the risk of endophthalmitis.<sup>16</sup> In this study, the culture result is found 50% of positive microorganisms. The most common isolated microorganism was *Staphylococcus Epidermidis* (23%). Other causative microorganisms were *Candida albicans* (6.3%), *Bacillus Sp* (6.3%), *Pseudomonas aeruginosa* (6.3%), and *Aspergillus Flavus* (6.3%). Other recent study also found that the most common microorganism was *Staphylococcus epidermidis* (77%).<sup>17</sup> Study by Das *et al.*<sup>11</sup> in India reported that 43.2% cases with positive cultures were found *Streptococcus epidermidis*. The causative microorganisms will affect the final visual acuity. Several studies reported that infection

by gram-positive bacteria and negative cultures had better final vision.<sup>5,13</sup>

The acute onset and progression of inflammation not only shows the immune host response to infection, but also describes the virulence of causative microorganism which is affecting final VA. Endophthalmitis, which occurs immediately after cataract surgery and develops rapidly, indicates infection by virulence microorganisms and is at risk of having poor visual outcome.<sup>14</sup> Most patients with post-cataract surgery endophthalmitis appeared with acute onset and within seven days after surgery, although in many cases it can occur later, especially in cases with causative agent such as fungal.<sup>6,7,14</sup> In this study, the onset were mostly found within <7 days (57.1%). Visual outcomes for those with onset ≤7 days 58.3% had better final VA, while cases with onset >7 days only 33.3% could get visual improvement.

The success rate of visual outcome after PPV in this study was 47.6%. Jeong *et al.*<sup>14</sup> reported a higher result of the improvement of final VA (20/40) reaching 51.8% after vitrectomy and intravitreal antibiotic injection. Other studies by Torabi *et al.*<sup>8</sup> and Gower *et al.*<sup>18</sup> reported final VA better than 6/60 after vitrectomy of 67.4% and 60%. This study shows the benefits of immediate vitrectomy to improve the final visual outcome even in cases with poor initial visual acuity. Therefore, prompt vitrectomy in post-cataract surgery endophthalmitis is an effective treatment and can improve the prognosis of final vision.

## Conclusion

Cataract surgery is the most common cause of exogenous endophthalmitis. The functional visual outcomes of endophthalmitis after cataract surgery were 47.6%. The shorter time between onset and vitrectomy, causative microorganism, and initial visual acuity are significant factors associated with visual outcome after PPV surgery in post-cataract endophthalmitis. Although many factors affecting visual outcomes in post-cataract surgery endophthalmitis, prompt PPV is an effective treatment that can improve the prognosis of visual acuity.

## References

1. Kernt M and Kampik A. Endophthalmitis: pathogenesis, clinical presentation, management, and perspectives. Clin Ophthalmol. 2010;4:121-35.
2. Hashemian H, Mirshahi R, Khodaparast M, Jabbarvand M. Post-cataract surgery endophthalmitis: brief literature review. J Curr Ophthalmol. 2016;28(3):101-5.
3. Taban M, Behrens A, Newcomb RL, Nobe MY, Saedi G, Sweet PM, et al. Acute Endophthalmitis Following Cataract Surgery: A Systematic Review of the Literature. JAMA Ophthalmol. 2005;123(5):613-20.
4. Friling E, Lundstrom M, Stenevi U, Montan P. Six-year incidence of endophthalmitis after cataract surgery: Swedish national study. J Cataract Refract Surg. 2013;39:15-21.
5. Results of the Endophthalmitis Vitrectomy Study: A Randomized Trial of Immediate Vitrectomy and of Intravenous Antibiotics for

- the Treatment of Postoperative Bacterial Endophthalmitis. *JAMA Ophthalmol*. 1995 Dec 1;113(12):1479–96.
6. Safneck JR. Endophthalmitis: A review of recent trends. *Saudi J Ophthalmol Off J Saudi Ophthalmol Soc*. 2012;26(2):181–9.
  7. Krause L, Bechrakis NE, Heimann H, Kildal D, Foerster MH. Incidence and outcome of endophthalmitis over a 13-year period. *Can J Ophthalmol*. 2009 Feb;44(1):88–94.
  8. Torabi H, Tabatabai S-A, Khodabande A. Treatment outcomes of post cataract surgery endophthalmitis in a tertiary referral center in Iran. *J Curr Ophthalmol*. 2018;30(2):152–5.
  9. Vaziri K, Schwartz SG, Kishor K, Flynn Jr HW. Endophthalmitis: state of the art. *Clin Ophthalmol*. 2015;9:95–108.
  10. Jiang T, Jiang J, Wang R, Lei J, Zhou Y. Visual Outcomes and Prognostic Factors after Pars Plana Vitrectomy for Traumatic Endophthalmitis. *Biomed Res Int*. 2017;2017(January 2004).
  11. Das T, Hussain A, Naduvilath T, Sharma S, Jalali S, Majji AB. Case control analyses of acute endophthalmitis after cataract surgery in South India associated with technique, patient care, and socioeconomic status. *J Ophthalmol*. 2012;2012:298459.
  12. Chen YH, CHEN JT, Tai MC, Chou YC, Chen CL. Acute Postcataract Endophthalmitis at Referral Center in Northern Taiwan: Causative Organisms, Clinical Features, and Visual Acuity Outcomes After Treatment. *Medicine*. 2017;96:49.
  13. Jeong SH, Cho HJ, Kim HS, et al. Acute endophthalmitis after cataract surgery: 164 consecutive cases treated at a referral center in South Korea. *Eye (London, England)* 2017;31:1456–62.
  14. Luz RA, Dall'oglio LPS, Silva FS, Ghirelli W, Padoveze MC. Endophthalmitis After Cataract Surgery: Result From Seven Years of Epidemiological Surveillance. *Rev Bras Oftalmol*. 2019;78(2):86-90.
  15. Hsu CM, Chen S C, Wu T T, et al. Outcomes of 23-gauge transconjunctival sutureless vitrectomy for acute postoperative endophthalmitis. *J Chin Med Assoc* 2017;80:503–7.
  16. Durand ML. Endophthalmitis. *Clin Microbiol Infect*. 2013;19(3):227-34.
  17. Wu Y, Yan XM. Retrospective analysis of the clinical characteristics and visual outcomes of postoperative endophthalmitis of cataract between 2001 and 2012. *Beijing Da Xue Xue Bao*. 2014;46:215-219.
  18. Gower EW, Keay LJ, Stare DE, Arora P, Cassard SD, Behrens A, et al. Characteristics of Endophthalmitis after Cataract Surgery in the United States Medicare Population. *Ophthalmology*. 2015;122 (8): 1625–32