

## EXPERIENCES OF SURGICAL MANAGEMENT OF FRACTURE SHAFT OF HUMERUS IN ADULTS USING ENDER NAIL

Dr. Amit Ranjan Vidyarthi<sup>1</sup>, Dr. Alok Sobhan Datta<sup>2</sup>

<sup>1</sup>Senior Resident, Orthopaedics, I.P.G.M E & R, Institute of Postgraduate Medical Education & Research, Kolkata

<sup>2</sup>Associate Professor, Orthopaedics, I.P.G.M.E & R, Institute of Postgraduate Medical Education & Research, Kolkata

**Article Info:** Received 13 April 2021; Accepted 04 June 2021

**DOI:** <https://doi.org/10.32553/ijmbs.v5i6.1992>

**Corresponding author:** Dr. Amit Ranjan Vidyarthi

**Conflict of interest:** No conflict of interest.

### Abstract

**Background:** This study was conducted at the Department of Orthopaedics, I.P.G.M.E & R & SSKM Hospital, Kolkata, West Bengal, with the objective to achieve quick union and minimal soft tissue disruption, least neurovascular complications and good functional outcome. In this study, 30 patients were selected on random basis from those attending the Outpatient Department and Emergency Room, between January 2015 to August 2016, with humerus shaft fractures. Among these, 76% of the patients were in age group (<40 years) with age range 22-60 years with mean age 35 years. The male : female ratio was 6.7:1. In our study majority (73%) of the patients have type AO 12A3 fracture. Mean duration of injury was 9.633 days. Mean duration of surgery in our study was 74.33 minutes, with range of 45-95 minutes, indicating a short operating time and minimum radiation exposure. During intraoperative period no complications and difficulties were experienced. The complications of our operative period were only 13%. Mean duration of follow up was 13.7 months with range from 9-18 months without any loss at follow up. All fractures united. Mean duration of union was 17 weeks. In this study, 80% patients had excellent grading, 17% have good grading and 3% had fair grading on the basis of **MEPS** and **UCLA score** combining shoulder and elbow functional outcome. In the present study, we dealt with the association of different parameters with respect to grading fracture pattern and type. This study showed that Ender's nailing for closed humerus shaft fracture provided satisfactory clinical, radiological, and functional outcome, was minimally invasive, had less infection rate and least neurovascular complications, thus promising a viable option for treatment of closed shaft humerus fracture.

**Keywords:** Closed fracture shaft Of humerus ; Adults, Minimally invasive , Ender's Nail ; Fracture union.

### Introduction

The humerus fracture is the second most common fracture of upper extremity and account for 3% to 5% of all fractures. The predominant cause of humerus shaft fracture include, in younger population from high energy trauma from road traffic accident, sports injuries or industrial accidents while in the elderly population, fall on an outstretched hand and fall from standing height, are common. About 40 to 60% of all humerus fractures occur in mid shaft while, 30 to 40% occur in proximal and 10 to 20% occur in distal humerus. Among these fractures, simple fractures account for 2/3 rd. of all fractures while more complex fractures involving spiral or multiple fragments account for rest of all humeral shaft fractures.

Treatment options for humeral fractures vary according to the type of fracture, age group, bone density, soft tissue status and associated complications. Several modalities are available for the treatment of humeral shaft fracture. Non-operative management continues as the mainstay for treatment of the majority of these injuries, with acceptable healing occurs in more than 90% of patients. Surgical intervention is indicated in special circumstances including (1) failure of closed reduction, (2) intra-articular extension of fractures, (3) neurovascular compromises, (4) associated ipsilateral forearm and elbow fractures, (5) segmental

fractures, (6) pathological fractures, (7) open fractures fractures in polytraumatised patients, (8) bilateral humeral shaft fractures, (9) periprosthetic fractures and (10) transverse or short oblique fractures. There is no consensus on the optimal modality of treatment when surgery is indicated. Most acute fractures can be dealt with a less invasive intramedullary nail and Ender's nails. Ender's nail is a flexible intramedullary nail for fixation of shaft humerus fracture. It can be inserted either antegrade or in a retrograde manner. The proximal entry of antegrade nailing may lead to rotator cuff injury, shoulder impingement, proximal nail migration and impaired shoulder function. In retrograde Ender nailing, the epicondylar entry portal ensures that no joint is breached. Ender's nailing system relies on configuration and spatial orientation of nail to achieve rotational stability. With reamed interlocking nails, rotational stability can be achieved through locking screws. The minimally invasive procedure for Ender nailing enables preservation of soft tissue, periosteum and fracture hematoma & provides flexible stability for biological union.

### Diagnosis:

Humeral shaft fracture is a common event and is estimated that these fractures comprise 3-5% of all fractures in adults.

The clinical evaluation of a patient with a humeral shaft fracture should comprise complete physical and neurovascular examination. Conventional radiographs in two planes are the standard diagnostic procedure.

The Holstein-Lewis fracture, an oblique fracture in the distal one third, is known for its association with radial nerve injury.

**IMAGING:** Standard imaging for humeral shaft fracture includes two orthogonal radiographs (at 90 degrees to each other) that include the shoulder and elbow joints in each view. CT scanning may be indicated in the rare situation where a significant rotational abnormality exists

Current non-operative management:

The current strategy for non-operative management involves the immediate immobilization of the injured extremity by a hanging cast, or coaptation splints, sling and swathes, long-arm casts, shoulder Spica casts, and olecranon pin traction to provide initial fracture stability, pain control, and resolution of the edema. However, while good results have been described with most of these methods, functional bracing has become the gold standard for non-operative treatment due to its ease of application, adjustability, low cost, allowance of shoulder and elbow motion, and reproducible record of success. Non-operative methods are associated with a significant risk of non-union, malunion, fracture disease & difficulty in nursing & rehabilitation in polytrauma cases.

Surgical treatment of humeral shaft fracture:

Indications:

- 1) Humeral shaft fracture with more than 20° of sagittal and 30° of coronal angulation and less than 5 cm of shortening.
- 2) Open fracture of shaft of humerus.
- 3) Shaft fracture associated with a neurovascular injury.
- 4) Fracture in a polytrauma patient.
- 5) Shaft fracture associated with ipsilateral fracture both bone forearm
- 6) Bilateral humeral shaft fractures.
- 7) Segmental humeral shaft fracture.
- 8) Humeral shaft fracture associated with an ipsilateral brachial plexus injury.
- 9) Pathological fractures.

#### **Intramedullary Nailing:**

The advent and success of intramedullary nailing (IMN) in the lower extremities led to an initial enthusiasm for intramedullary nailing of the humeral shaft, but without equal success. This technique could be used to stabilize fractures that were 2 cm below the surgical neck to 3 cm proximal to the olecranon fossa.

#### **Advantage:**

1. Exposure required is less thus decreasing the infection rate and soft tissue scarring with higher union rate.
2. Nails can act as load sharing devices, it will act as a gliding splint and allow fracture compression as the extremity is loaded.
3. In midshaft fractures, nails that fill the medullary canal automatically re-establish osseous alignment.
4. Stress shielding with resultant cortical osteopenia, commonly seen with plates and screw, is minimized with these.
5. Refracture after implant removal is rare, secondary to lack of cortical osteopenia, and the fewer stress risers created.
6. They are subjected to smaller bending loads than plates because it is closer to the mechanical axis than the usual plate position on external surface.
7. Lesser chances of iatrogenic radial nerve palsy.

#### **Disadvantages**

1. Nail migration
2. Additional external immobilization is required
3. Non-union rate is high because of distraction due to gravity and other factors
4. Mal union (specially rotatory) are quite common
5. Subacromial impingement causing shoulder pain and decreased shoulder motion
6. In case of distal entry of nail there can be limitation of elbow movements, myositis and iatrogenic fracture.
7. Nailing interferes with endosteal blood supply.
8. Technical problems of interlocking nails are encountered.

#### **PATIENT SELECTION CRITERIA:**

##### **Inclusion criteria**

1. Closed fracture shaft of humerus
2. Fracture of variable duration were selected
3. Adult Age group >15 YEARS
4. Both sexes (MALE & FEMALE)
5. Those willing to participate in the study through written consent.

##### **Exclusion criteria**

1. Patients with comorbid conditions not fit for surgery
2. Patient unwilling to undergo surgery
3. Open fracture shaft of humerus
4. Intercondylar and supracondylar fracture of humerus.
5. Shoulder pathology patient

6. Moribund patients

**Age group < 15 YEARS**

**STUDY DESIGN:**

This was an institution based case series study. Patients were evaluated clinico- radiologically using **Range of Movement(R.O.M)** and **digital AP & Lateral view radiographs** in serial follow- up:

- 1) Just after operation;
- 2) at 2<sup>nd</sup> ;5<sup>th</sup> and at the end of 8<sup>th</sup> week.

They were then followed up for 1year with radiological evaluation .

**IMPLANT USED FOR FRACTURE FIXATION**

1. 3.0/ 3.5/4.0 mm Ender's nails.
2. Instrumentation set.( IMPACTER , NAIL BENDER, NAIL EXTRACTER)
3. AWL

**Parameters Studied:**

Evaluation of the short and long- term benefits of surgical management of fracture shaft of humerus by **Ender nail** by:

- a) Range of movement
- b) R radiologically(AP&LATERAL VIEW)
- c) UCLA SHOULDER RATING SCALE.
- d) MAYO ELBOW PERFORMANCE SCORE.

**STUDY TOOL:**

\**Clinical methods*

\* *Radiographs*

\* *CT Scan, if required.*

\***ENDER'S NAILS** of various sizes  
\***INSTRUMENTATION SET FOR ENDER'S NAILING**

\*Demographic data of all the patients who are admitted in ward. (*Case Record form*)

**Study technique:**

The operation was performed under brachial block or general anesthesia. All patients received one dose of prophylactic intravenous antibiotic (Cefuroxime,1.5gm). A careful pre-operative planning to assess the medullary canal diameter on radiographic films was made to assess the appropriate number and size of nails, in a good spatial distribution. Before antiseptic preparation, the fracture was manipulated under fluoroscopy to assess the reducibility and maneuvers required therefore. The patient was positioned supine with the arm placed on the side on an arm rest. Incisions were placed on the palpable subcutaneous lateral and medial epicondyles. Care was taken to protect the ulnar nerve on the medial side. The tips of the

epicondyles were used as entry portals. The elbow was maintained at 90° flexion to facilitate palpation of the epicondyles and for Insertion of a curved awl under imaging to direct the track well into the medullary canal. First a *C* or *S*-shaped **Ender's nail** was inserted from either entry portals depending on the fracture geometry, and advanced to the fracture site. After appropriate manipulation under fluoroscopy, the nail was advanced to the subchondral part of the humerus head. Length of the nails was confirmed under image intensifier before the final impaction. Depending upon the fracture geometry and stability achieved the decision to provide an external support with a humerus brace was made. The brace would support the upper arm only and the patients would be encouraged to move the elbow and shoulder joint slowly first passively & then actively gradually after 2 weeks.

**POST OPERATIVE PROTOCOL:**

- **After 48hours:**Wound inspection and post -operative X-Ray on second day
- **First week:** Passive mobilisation of shoulder & elbow
- **Second week onwards :**Active mobilisation
- **12th day :**Suture removal
- **Fourth week onwards:**Progressive increase in weight lifting
- **Serial x rays in 4-6weeks interval** to look for the fracture union.

**Follow up**

Patients were discharged at 1 week postoperatively. All the patients were followed up and **anteroposterior and lateral** radiographs were obtained **every 4-6weeks** until bony union was achieved.

**Data Collection**

**Operative time** was defined as the time from skin incision to closure. **Union** was defined as the absence of pain and presence of bridging callus at fracture site on radiographs. **Nonunion** was defined as the absence of fracture union 6 months postoperatively and no sign of further fracture healing. **Malunion** was defined as an angle of 2 parts of the line of the previous fracture segment greater than 15° (range: 15°-90°). **Follow-up time** was defined as the duration between the operation and the last regular follow-up before this article was compiled. **Shoulder and elbow ROM** were measured using a goniometer at the time of union. Postoperatively, **operative time, intraoperative blood loss, and time to union** were compared. Clinical assessment consisted of using the **American Shoulder and Elbow Surgeons scoring system** for shoulder joints and **Mayo performance score** for elbow joints. **Higher scores in both systems correspond with better joint function.** Ranges of motion and muscle power were rated by comparing the injured and uninjured arms. Functional recovery at final follow-up was compared between 30 patients who

underwent *Minimally Invasive Plate Osteosynthesis*(MIPO). Complication such as nonunion, malunion, infection, nerve injury, nail back out, triceps tendon injury and implant failure, were also observed during follow-up. Due to intraoperative radiation exposure, the time of exposure was collected. Union rates were also compared.

#### Statistical Analysis

The data collected from the patients – age sex, injured side, rate of associated injuries, rate of postoperative complication and fracture characteristics were analyzed using **SPSS version 16 software** (SPSS, Inc. Chicago, Illinois). Independent sample *t test* was used to compare the results of patient's age, duration of injury, operation time, duration of follow-up, healing time, range of motion of the shoulder and elbow and score of *UCLA* and *MEPS*.

#### Data Analysis:

For statistical analysis data were entered into a Microsoft excel spreadsheet and then analyzed by **SPSS 20.0.1** and **GraphPad Prism version 5**. Data have been summarized as mean and standard deviation for numerical variables and count and percentages for categorical variables. The median and the interquartile range have been stated for numerical variables that are not normally distributed. *Student's independent sample's t-test* was applied to compare normally distributed numerical variables between groups; Un -paired proportions were compared by *Chi-square test* or *Fischer's exact test*, as appropriate.

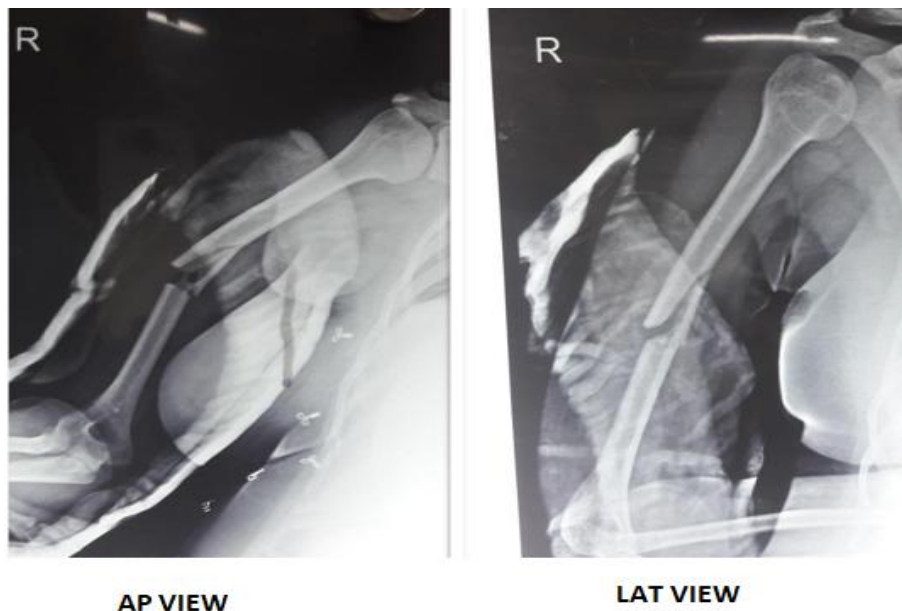
Once a *t value* was determined, a *p-value* could be found using a table of values from Student's t-distribution. If the calculated *p-value* was below the threshold chosen for statistical significance (usually the 0.10, the 0.05, or 0.01 level), then the null hypothesis was rejected in favor of the alternative hypothesis.

$p\text{-value} \leq 0.05$  was considered statistically significant.

Treatment of humerus shaft fracture has evolved from the *conservative cast and brace* (Camden P and Nade S., 1992, Hunter SG., 1982) to *internal fixation with plate and screws* (Chao TC et al., 2005) and *intramedullary nailing* (Chao TC et al., 2005); each of these techniques has its own complications (Chao TC et al., 2005, Ajmal M et al., 2001, Petsatodes G et al, 2004, Santori FS et al., 2002) and there is *no significant data that shows the superiority of one over the other*. Most acute fractures could be dealt with less invasive intramedullary nail , Rush nails or Ender's nails. It involved minimal soft tissue dissection and was a closed technique where the biology of fracture site was undisturbed. Being minimally invasive Ender's nailing could be accepted as promising method of management of fracture shaft of humerus and was well supported by the studies. However, there were no large series of data that reported the advantages and disadvantages of Ender's nailing compared with conventional plate-osteosynthesis , and other intramedullary nailing technique. The aim of this study was to determine the radiological and functional outcome along with effectiveness of simple and economical Ender's nailing in management of closed fracture shaft of humerus in adults.

### CASE 1

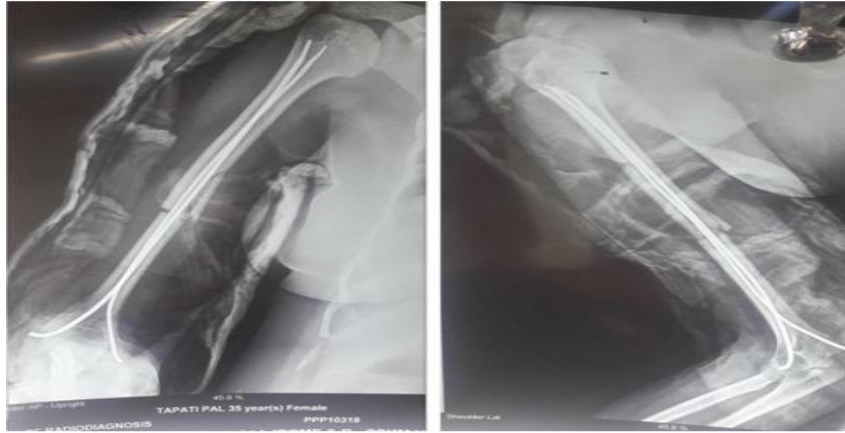#### PREOPERATIVE X-RAY



AP VIEW

LAT VIEW

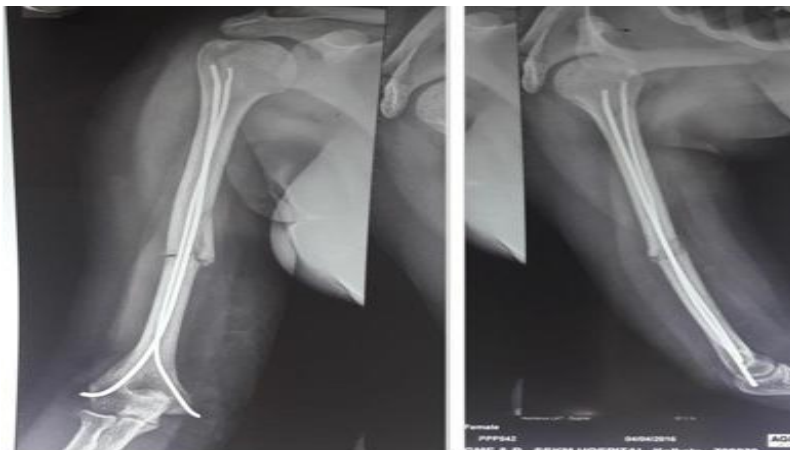**IMMEDIATE POST OP**



**AP VIEW**

**LAT VIEW**

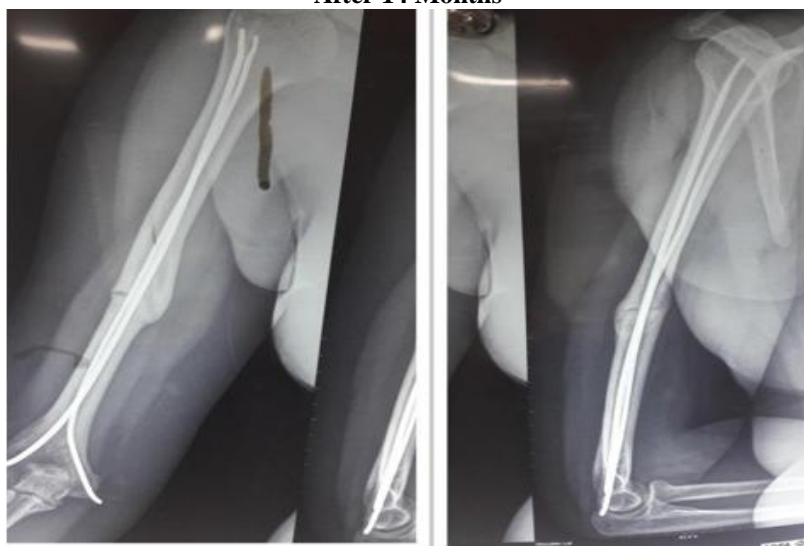**After 3 Months**



**AP VIEW**

**LAT VIEW**

**After 14 Months**



**AP VIEW**

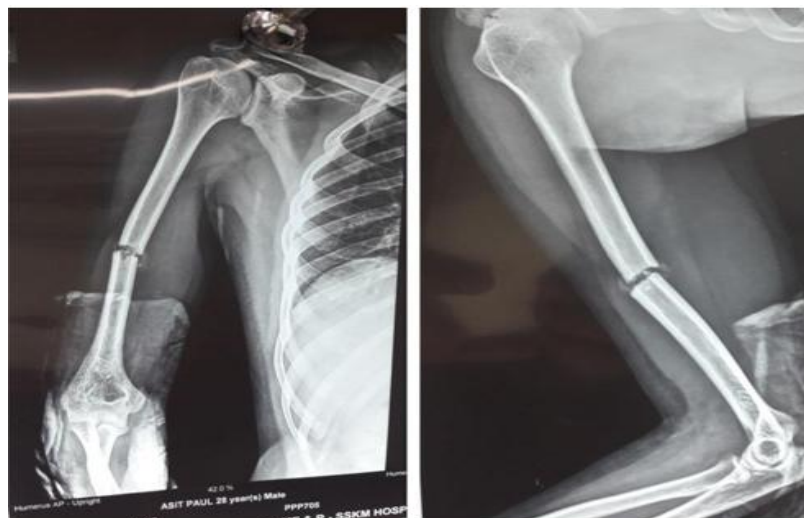
**LAT VIEW**

**CLINICAL PICTURE OF CASE 1**



**CASE 2**

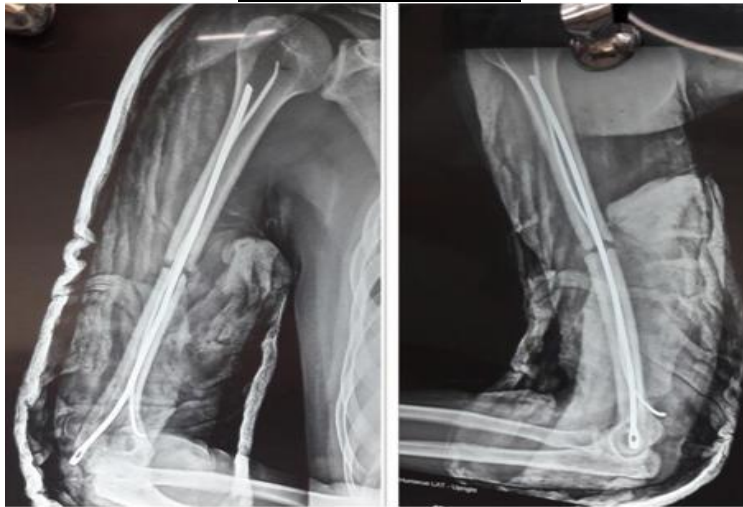**PREOPERATIVE X-RAY**



**AP VIEW**

**LAT VIEW**

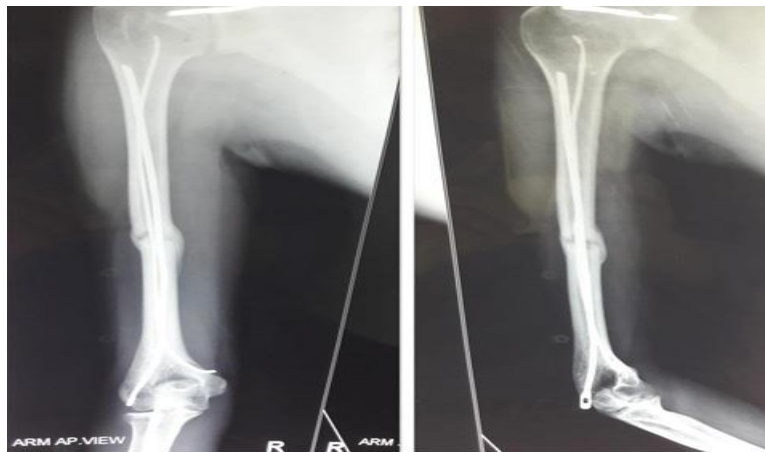
**IMMEDIATE POST OP**



**AP VIEW**

**LAT VIEW**

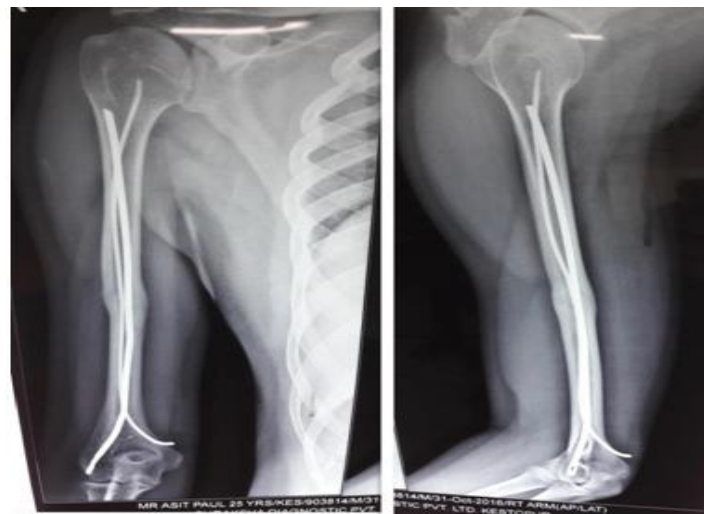
**After 3 Months**



**AP VIEW**

**LAT VIEW**

**After 14 Months**



**AP VIEW**

**LAT VIEW**

**CLINICAL PICTURES OF CASE 2****Conclusion:**

This work presents the use of *Ender's nail* in the management of closed humeral shaft fractures in adults. The results obtained in this study have shown that *Ender's nailing* in the surgical management of closed fracture shaft of humerus was safe, convenient and effective, since there was minimal soft tissue injury, nor any major complications, including less operative scars and better cosmesis. The reported outcomes of Ender's nailing have been favourable, with rapid stabilisation of the fracture site by bridging callus, progressing to complete union with least infection rate and neurovascular injury; preservation of soft tissue, periosteum and fracture haematoma provided flexible stability for biological union. From this *prospective comparative* study, we conclude that in the surgical management of fracture shaft of humerus, Ender's nail was a viable option .

**References:**

1. ROCKWOOD AND GREEN'S Fracture in adults 8<sup>th</sup> edition page no 1287
2. Schemitsch EH and Bhandari M, Fracture of humeral shaft In: Browner BD, Jupiter JB. LevineAMTrafton PG Skeletal Trauma: Basic science,management and reconstruction p 1487-1448
3. Changulani M et al. Comparision of the use of the humerus intramedullary nail and dynamic compression plate for the management of diaphysial fractures of humerus 2007.
4. Khurana A, Pendse A, Modi H, Diwanji S, Mathur H, Daveswar R . Retrograde Ender nailing for humerus shaft fractures (2009) (15)
5. Hoppenfeld S and deBoer P., , Surgical Exposures in Orthopaedics: the anatomical approach 2003

6. Epps CH Jr and Grant RE Fracture of shaft of humerus In: Rockwood CA Jr, Green DP, Bucholz RW, editors. Rockwood and Green's fractures in adults. 3rd ed. Philadelphia: Lippincott Williams & Williams; 1991.
7. Pollock FH, Drake D, Bovill EG, Day L, Trafton PG. Treatment of radial neuropathy associated with fractures of the humerus. *J Bone Joint Surg Am* 1981;63:239-43. radial nerve palsy in patients with acute humeral shaft fractures
8. Chiu FY, Chen CM, Lin CF, Lo WH, Huang YL, Chen TH. Closed humeral shaft fractures: a prospective evaluation of surgical treatment. *J Trauma* 1997;43:947-51.
9. Shetty MS; Kumar MA;Sujay K, Kini AR, Kanthi KG. Minimally invasive plateosteosynthesis for humerusdiaphysealfractures.*Indian J Orthop.* 2011, Nov; 45(6): 520-6. doi: 10.4103/0019-5413.87123.
10. Foster RJ Dixon GL Jr, Bach AW, Appleyard RW, Green TM. Internal fixation of fractures and non-unions of the humeral shaft. Indications and results in a multi-center study. *J Bone JointSurgAm*1985; 67:85764
11. Campbell's Operative Orthopaedics,12<sup>th</sup> edition.