

AN ANALYTICAL STUDY TO ASSESS AND COMPARE OUTCOME OF CLIPPING VERSUS SUTURE LIGATION OF THE CYSTIC DUCT IN LAPAROSCOPIC CHOLECYSTECTOMY

Lakhami Chand Sinsinwar¹, Rajvala Choudhary², Sanjeev Singh Choudhary³, Jeevan Kankaria⁴

¹Junior Resident, Department of Surgery, SMS Medical College, Jaipur

²Junior Resident, Department of Pathology, RUHS Medical College, Jaipur

³Senior Resident, Department of General Surgery, SMS Medical College, Jaipur

⁴Professor, Department of General Surgery, SMS Medical College, Jaipur

Article Info: Received 05 July 2021; Accepted 20 August 2021

DOI: <https://doi.org/10.32553/ijmbs.v5i8.2143>

Corresponding author: Lakhami Chand Sinsinwar

Conflict of interest: No conflict of interest.

Abstract

Background: Laparoscopic cholecystectomy (LC) has been performed for decades and fairly standardized procedure throughout the world. Ligation of cystic duct is popularly done with the help of metal clips (MC). Suture ligation (SL) of the cystic duct is one such way which is simple, secure and cost-effective technique. In this study two groups are compared, one in whom metal clips were used and in other suture ligation of the cystic duct.

Methods: This study is done in Department of General Surgery, SMS Hospital, Jaipur. This is a hospital based prospective study conducted from 1 June 2018 to 30 March 2019.

Results: The difference of intra-operative complication like bleeding, bile spillage, CBD injury, visceral injury in two groups was found statistically not significant.

Conclusion: We concluded that the use of suture for ligation is a very cost effective and economic option for ligation

Keywords: LC, MC, SL

Introduction

Laparoscopic cholecystectomy (LC) has been performed for decades and fairly standardized procedure throughout the world. Ligation of cystic duct is popularly done with the help of metal clips (MC). Suture ligation (SL) of the cystic duct is one such way which is simple, secure and cost effective technique. In this study two groups are compared, one in whom metal clips were used and in other suture ligation of the cystic duct.

The conception of laparoscopy has revolutionized the art of surgery due to its advantages over classical open technique. The lately innovated laparoscopy cholecystectomy has been drastically refined over the years by better understanding of ergonomics, instrumentation of new energy sources and endosuturing.

The conventional four ports access technique has been modified to three ports, two ports and single incision laparoscopic surgery with corresponding results. Further cystic duct closure methods like clipping, harmonic scalpel and intra corporeal ligation have been tried with gratifying results.

Metallic clip is the most commonly used method for cystic artery and duct closure which may be due to ease of learning and its execution, short operative time and time-tested safety of technique. Although it is not less than boon for a budding surgeon but it is not free from complications. Bile leaks,

migration of clip, inadvertently clipping of common bile duct and right hepatic artery have been reported in literature.

Material and Methods

This study is done in Department of General Surgery, SMS Hospital, Jaipur. This is a hospital based prospective study conducted from 1 June 2018 to 30 March 2019. Every eligible case of cholelithiasis admitted in the department of surgery, SMS Medical College, Jaipur, the sample size undergoing laparoscopic cholecystectomy.

Inclusion Criteria: 1. Those patients who have given written and informed consent. 2. All patients undergoing laparoscopic cholecystectomy.

Exclusion Criteria: 1. Patients who are undergoing subtotal cholecystectomy. 2. Those patients who have not given written and informed consent.

Results

The present study was conducted in Department of Surgery, Sawai Man Singh, Medical College and Attached Group of Hospitals, Jaipur, Rajasthan in which 100 patient laparoscopic cholecystectomy were evaluated. These 100 patients were allocated in two groups of 50 each. These 50 patients in each group successfully underwent laparoscopic cholecystectomy according to study protocol and follow up was completed in all patients.

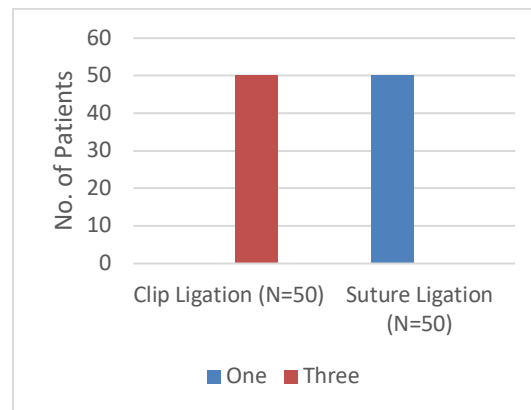
We found that there is no statistical significant differences were found in the age distribution. The mean age was 41.70 with 13.59 (SD) in clip ligation group and 44.14 with 18.26 (SD) in suture ligation group. Sex distribution amongst the

study population which was found to be comparable between the groups with the difference being statistically insignificant with p value 0.65 which is >0.05 .

Table 1: Distribution of ligation time in study groups

Ligation Time (In Minutes)	Clip Ligation (N=50)		Suture Ligation (N=50)		Total (N=100)		P-Value
	N	%	N	%	N	%	
1	15	15	0	0	15	15	<0.001
1.5	10	10	0	0	10	10	
2	16	16	15	15	31	31	
2.5	5	5	15	15	20	20	
3	4	4	15	15	19	19	
3.5	0	0	5	5	5	5	
Total	50	50	50	50	100	100	

In table 1, we found that the difference in mean duration of cystic duct ligation by two methods. The mean duration of cystic duct ligation while using clip ligation was 1.73 minutes compared to 2.60 minutes using suture ligation. The difference was statistically significant.



Graph 1: Clips or sutures used in both groups

In graph 1, we showed clips or sutures used in both groups. In table 2, we showed the comparison of intra-operative complication like bleeding, bile spillage, CBD injury, visceral injury in two groups. The difference was not significant statistically. Table 2 highlights the increased incidence of bile spillage in clip ligation group.

Table 2: Intra-operative complication observed in both groups

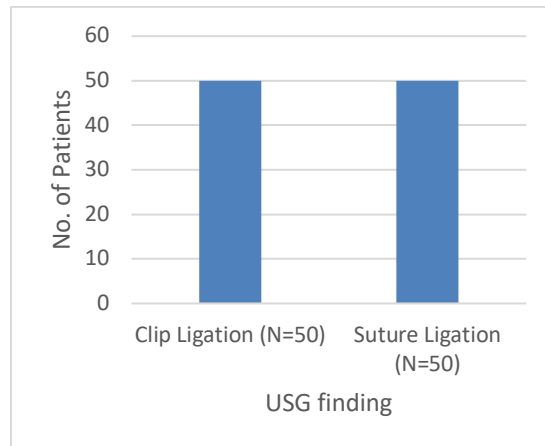
Intra-operative Complications	Clip Ligation (N=50)		Suture Ligation (N=50)	
	N	%	N	%
Bleeding	0	0	0	0
Bile Spillage	2	4	0	0
CBD Injury	0	0	0	0
Visceral Injury	0	0	0	0
Nil	48	96	50	100
Total	50	100	50	100

The placement of intra-abdominal drain was a rule for every case. A 24 French size soft drain was used, which was placed in Morrison's Pouch. Content of drain was measured for 24 hours and if it increased, patient was kept under watchful eyes. In two groups didn't have any discharge in any case. This difference was found to be insignificant.

Table 3: Duration of hospital stay in both groups

Duration of hospital stay (In days)	Clip Ligation (N=50)		Suture Ligation (N=50)	
	N	%	N	%
1 Day	50	100	50	100
Total	50	100	50	100

Table 3 summarizes the duration of hospital stay of patients in the two groups after surgery. All patients were discharged on the day 1st post-surgery. In graph 2, we found distribution of USG findings in both groups.



Graph 2: Distribution of USG findings in both groups

Discussion

Laparoscopic cholecystectomy is being increasingly performed as a day care surgery procedure. Evidence showed that there was no significant difference in morbidity between day surgery procedure and overnight stay, and both approaches had similar prolonged hospitalization and readmission rate. In addition, there was no significant difference in the visual analogue scale score, postoperative nausea and vomiting scale, time to return to activity and work between the two groups. Laparoscopic cholecystectomy can be performed safely in selected patients as a day surgery procedure. The cystic duct and artery are normally closed with titanium clips. No bile leakage or other problems were reported with intracorporeal ligation of the cystic duct/artery by silk 2/0. The time required for tie varied from 2 minutes to 3.5 minutes.

Another study reported that the time from skin incision to closure of wound was 46.6 minutes in the clip group and 70.7 minutes in the ligation group.¹ The authors observed that the operative time was longer when using intracorporeal knotting as compared with clip application, but the difference was not statistically significant ($P=0.493$). Ghavidel A *et al*² found that post-cholecystectomy clip migration was rare, but could lead to complications such as clip-related biliary stones. Most of such incidents have been reported as case reports in the literature. It can occur at any time but mostly after a median period of two years post-cholecystectomy. In our group, there was no such complication neither any leakage from the bile duct was observed in the postoperative period. Other authors observed more benefits of the simple ligation of cystic duct. It is easy and practical.

This is a simple technique that could be performed without any difficulty. Beyond doubt, simple ties are always available and very economic. Mehmedovic Z *et al*³ declared that LC was associated with a higher risk of intraoperative lesions and primarily lesions of biliary ducts. In a small

percentage of cases, biliary fistulas occur, most commonly after leakage from cystic duct stump or accessory bile ducts. Our study observed that with the tight secure of silk to the cystic duct, the colour of the duct changed to white.

An author described an intraductal migration of surgical clips into the CBD after 10 years of LC, which was unusual and could result in gallstone formation- clip cholelithiasis. Photi ES *et al*⁴ have done the ligation of the cystic duct with surgical clips, and reported a case of cholangitis secondary to clip migration into the CBD. Another case was reported as postoperative Mirizzi syndrome caused by the migration of four polymer laparoscopic clips, which could confuse the diagnostic and therapeutic field for treatment. A study reported a case of bile leak caused by an injury to the ducts of Luschka after LC; the leak was treated with Endoscopy and Stenting. In our study, no such complication was encountered. We applied the clips with keeping the distance from the cystic duct- CBD junction, which may be the reason of non-migration of clips into the CBD. Though it was our observation, large series of studies are required to give a concrete evidence. We believe that, if LC is performed safely and meticulously, then complications may be decreased. The cystic duct or artery vice versa could be ligated separately with a piece of thread, though there were no major differences in the form of timing. In our study, the cost of silk suture was much cheaper than that of titanium clips used for the cystic duct and artery. Suture material used during the study, approximate cost of Rs. 120-130 while for metallic clip cost was around Rs. 700-1000. This suggests that the use of suture for ligation is a very cost effective and economic option for ligation. In the present study, surgery was performed by a single surgeon to avoid complications, as operating time would vary among surgeons.

Conclusion

The advantages of the present study include: 1. Suture ligation needs skills and experience, which can be

improved by training. 2. When the colour of the cystic duct becomes white, it means that silk tied to the cystic duct is secure enough. 3. Suture is readily available everywhere, but the availability of clips can be sometimes questioned even in terms of appropriate size. 4. The cost of clips is much higher than that of silk.

Bibliography

1. Singal R, Shama A, Zaman M. The Safety and Efficacy of Clipless versus Conventional Laparoscopic Cholecystectomy – our Experience in an Indian Rural Center. *Laparoscopy cholecystectomy. A Journal of Clinical Medicine* 2018;13(1).
2. Ghavidal A. Migration of Clips after Laparoscopic Cholecystectomy; A Case Report and Literature Review. *Middle East Journal of Digestive Diseases* 2015; 7(1).
3. Mehmedovic Z, Mehmedovic M, Hasanovic J. A Rare Case of Biliary Leakage after Laparoscopic Cholecystectomy–Diagnostic Evaluation and Nonsurgical Treatment: a Case Report. *Case Report / ACTA Inform Med.* 2015; 23(2) : 116-119.
4. Photi E S, Partridge G, Rhodes M, Lewis M P N. Surgical clip migration following laparoscopic cholecystectomy as a cause of cholangitis. *JSCR* 2014; doi:10.1093/jscr/rju026.