

PREVALANCE OF PULMONARY & RADIOLOGICAL MANIFESTATIONS IN SCRUB TYPHUS PATIENTS IN INDEX MEDICAL COLLEGE, INDORE

¹Dr. Shiv Kumar Pandey (Junior Resident 3rd Year), ²Dr. Vishal Malviya (Junior Resident 3rd Year), ³Dr. Kumar Girendra (Professor & HOD) & ⁴Dr. Abhijeet Khandelwal (Associate Professor)

^{1,2,3&4}Dept. of Respiratory Medicine, Index Medical College Hospital & Research Centre, Indore, M.P.

Article Info: Received 20 August 2021; Accepted 29 September 2021

DOI: <https://doi.org/10.32553/ijmbs.v5i10.2235>

Corresponding author: Dr. Vishal Malviya

Conflict of interest: No conflict of interest.

Abstract

Background & Method: 20 patients with scrub typhus who visited Index Medical College Hospital & Research Centre, Indore. Diagnosis of scrub typhus was made from blood samples based on serology (scrub typhus IgM / IgG antibody). We observed the following symptoms – eschar, cough, SOB, fever, chest pain, nausea /vomiting, abdominal pain, seizures, & the various laboratory investigations were done (TLC, ESR, S.CREATINE, LFT, SERUM ELECTROLYTES ETC.). CXR (PA / AP) were analysed on the basis of the presence, location and zonal predilection for consolidations, reticulo nodular shadows, hilar shadows and lower lobe haziness.

Conclusion: Pulmonary manifestation of Scrub typhus is uncommon. But can be fatal, particularly in the form of ARDS. Antibiotic therapy may prove beneficial in initial phase. In acute febrile illness (SCRUB TYPHUS), pulmonary symptoms and radiological manifestations should be rule out in early stages to prevent the mortality.

Keywords: Prevalance, Pulmonary, Radiological & Scrub Typhus.

Introduction

Scrub typhus, also known as tsutsugamushi disease, is an acute febrile illness caused by infection with *Orientia tsutsugamushi* and characterized by focal or disseminated vasculitis and perivasculitis, which may involve the lungs, heart, liver, spleen, and central nervous system (1–3). Scrub typhus is a public health problem in Asia, where about 1 million new cases are identified annually and 1 billion people may be at risk for this disease (4). In addition, reports of infection are becoming increasingly common in travelers returning from

Asia to their home countries (5, 6). The symptoms are usually mild and the clinical course self-limited, with spontaneous recovery after a few days; however, some cases are more severe and protracted, and the disease may be fatal. The diagnosis of scrub typhus is based on the patient's history of exposure, the clinical features, and the results of serologic testing (7, 8). The radiologic findings of scrub typhus are varied and nonspecific (9). Nevertheless, an awareness of the related findings at imaging, especially at computed tomography (CT), may facilitate accurate diagnosis.

Scrub Typhus is also known as Tsutsugamushi disease. It is as bacterial infection transmitted by Larval Trombiculid Mites. Causative agent – *Orientia Tsutsugamushi*, is an intracellular bacterium leads to eschar formation at inoculation site.

Symptoms–fever, headache, myalgia, generalized lymphadenopathy, cough, GIT symptoms, acute renal failure etc.

Aim- to estimate prevalence of pulmonary manifestations and radiological findings in scrub typhus patients, visited Index Medical College, Indore

Objectives

- To determine the frequency of pattern of pulmonary symptoms in scrub typhus patients.
- To determine frequency of pattern of Cxray findings in patients with scrub typhus.

Material & Method

Observational study was done of 20 patients with scrub typhus who visited Index Medical College Hospital & Research Centre, Indore from 1st August 2019 to 30th July 2021.

Diagnosis of scrub typhus was made from blood samples based on serology (scrub typhus IgM / IgG antibody).

We observed the following symptoms – eschar, cough, SOB, fever, chest pain, nausea /vomiting, abdominal pain, seizures, & the various laboratory investigations were done (TLC, ESR, S.CREATINE, LFT, SERUM ELECTROLYTES ETC.).

CXR (PA / AP) were analysed on the basis of the presence, location and zonal predilection for consolidations, reticulo nodular shadows, hilar shadows and lower lobe haziness.

Inclusion criterias- Age > 16 years & no previous history of pulmonary disease.

Exclusion criterias - Patients having chronic pulmonary disease (pneumonia, bronchiectasis); with cardiovascular illness; immune compromised patients.

Results

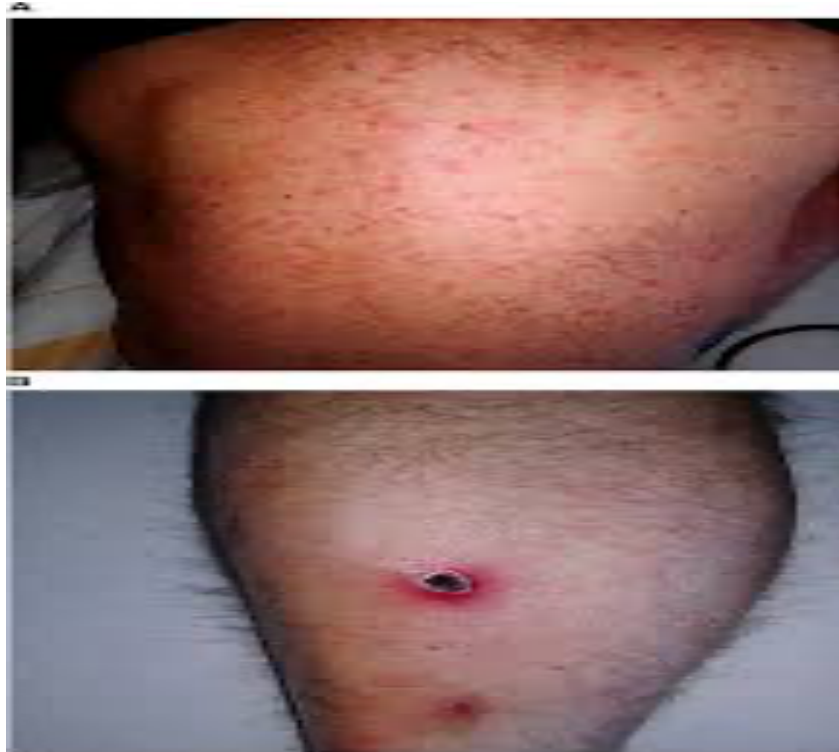

Figure 1: Centrifugal macular rash on the trunk & typical eschar at site of inoculation

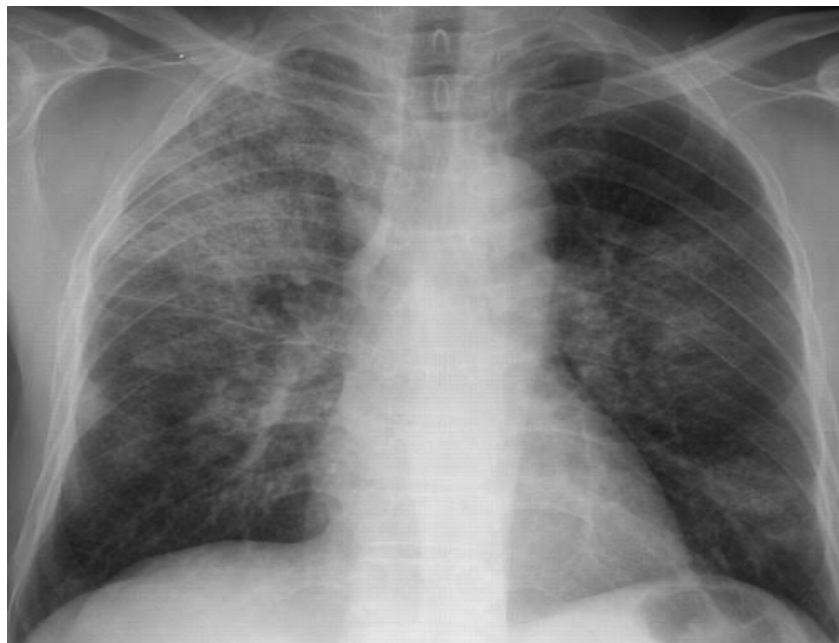

Figure 2: X-ray chest showing bilateral infiltration

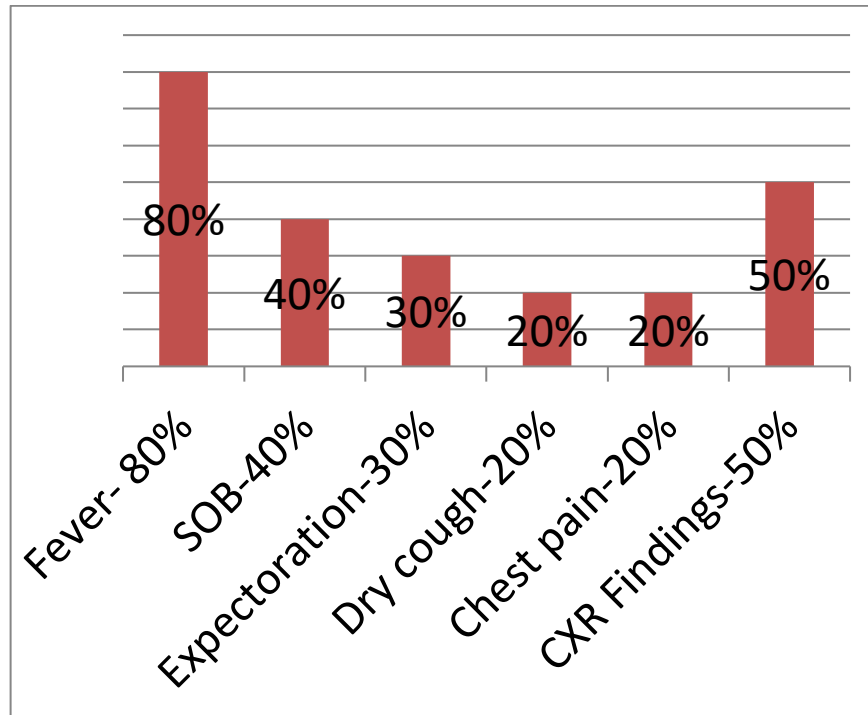


Figure 3: Clinical findings during the study

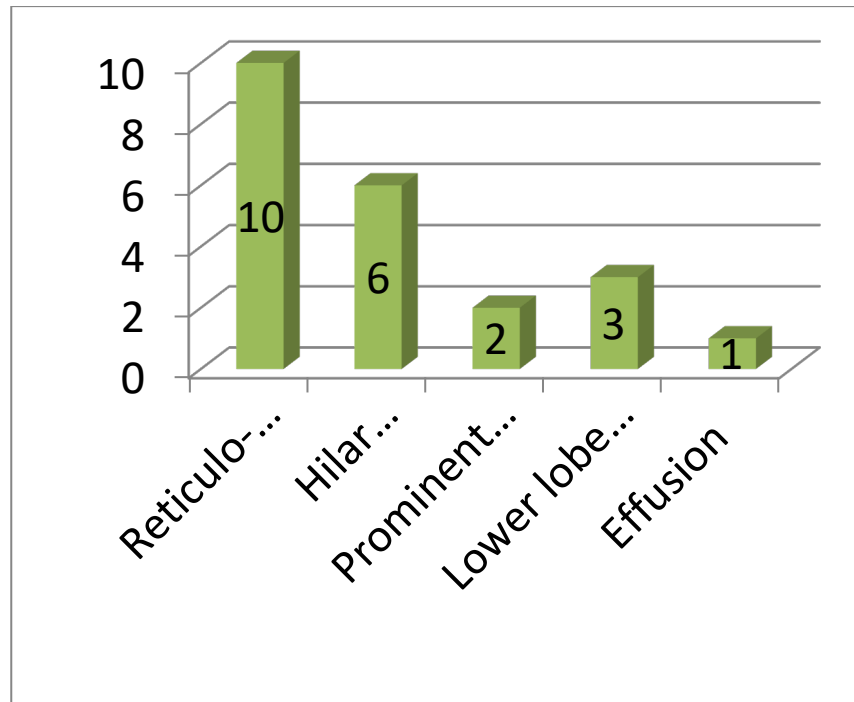


Figure 4: Radiological findings during the study

Discussion

IP frequently occurs in the acute stage of scrub typhus, but the impact of IP (Interstitial Pneumonia) on severity of the disease has not yet been reported. To evaluate the clinical role of IP as a marker of severity of the disease, we studied

101 patients with scrub typhus in a single center over 10 yr. Our data demonstrated that IP (Interstitial Pneumonia) was a common finding in the acute stage of scrub typhus, and it was closely associated with severity of the disease(10). To our knowledge, this is the first report in the medical literature

demonstrating the relationship between IP and severity of the disease among patients with scrub typhus.

The characteristic pathophysiologic findings in scrub typhus are well known. Multiplication of the organisms in the endothelial cells lining the small blood vessels causes an endothelial proliferation and perivascular inflammatory cell infiltration, and it results in rash, hemorrhage, and microthrombi. The result is a widespread infectious vasculitis or perivasculitis (11). Such microangiopathies may involve the heart, lungs, brain, kidneys, gastrointestinal tract, liver, spleen and lymph nodes (1, 4, 6, 8-10). The clinical parameters representing the severity of the disease are known to be hypotension, thrombocytopenia, leukocytosis, hypoxia, acute renal failure, hypoalbuminemia and hepatic dysfunction (3, 5-7). Although IP frequently occurs in the patients with scrub typhus, its exact pathophysiologic mechanism is not well known. The marked dilatation and congestion of septal capillaries, extravasation of red blood cells into the alveoli, and septal widening by the lymphocytes, histiocytes and a few polymorphonuclear leukocytes were found in the lung of mice infected with the rickettsia (12). When considering this pathologic study and the fact that the main pathogenesis of scrub typhus is widespread microangiopathy, we suggested that this microangiopathic lesion could be associated with the causes of IP (13). Therefore, we assumed that IP (Interstitial Pneumonia) would be associated with other clinical parameters that represent the severity of the disease.

Conclusion

Pulmonary manifestation of Scrub typhus is uncommon. But can be fatal, particularly in the form of ARDS. Antibiotic therapy may prove beneficial in initial phase. In acute febrile illness (SCRUB TYPHUS), pulmonary symptoms and radiological manifestations should be ruled out in early stages to prevent the mortality.

References

- Megan E, Reller J and Dumler S. Scrub typhus (Orientia tsutsugamushi). In: Kliegman RM (ed.) Nelson textbook of paediatrics. Philadelphia: Elsevier, 2016, p. 1504.
- Narayanasamy, DK, ArunBabu, T, Vijayadevagar, V, et al. Predictors of severity in pediatric scrub typhus. *Indian J Pediatr* 2018; 85: 613–617.
- Kumar Bhat, N, Dhar, M, Mittal, G, et al. Scrub typhus in children at a tertiary hospital in north India: clinical profile and complications. *Iran J Pediatr* 2014; 24: 387–392.
- Abhilash, K, Mannam, PR, Rajendran, K, et al. Chest radiographic manifestations of scrub typhus. *J Postgrad Med* 2016; 62: 235–238.
- Wu, KM, Wu, ZW, Peng, GQ, et al. Radiologic pulmonary findings, clinical manifestations and serious complications in scrub typhus: experiences from a teaching hospital in eastern Taiwan. *Int J Gerontol* 2009; 3: 223–232.
- Scott, JA, Wonodi, C, Mod'isi, JC, et al. The definition of pneumonia, the assessment of severity, and clinical standardization in the Pneumonia Etiology Research for Child Health study. *Clin Infect Dis* 2012; 54: S109–S116.
- World Health Organization. Revised WHO classification and treatment of childhood pneumonia at health facilities. Implications for policy and implementation, Geneva: World Health Organization, 2014.
- O'Grady, KF, Torzillo, PJ, Frawley, K, et al. The radiologic diagnosis of pneumonia in children. *Pneumonia* 2014; 5: 38–51.
- Keller, CA, Hauptmann, M, Kolbaum, J, et al. Dissemination of *Orientia tsutsugamushi* and inflammatory responses in a murine model of scrub typhus. *PLoS Negl Trop Dis* 2014; 8: e3064–e3064.
- Chauhan, V, Thakur, A, Thakur, S. Eschar is associated with poor prognosis in scrub typhus. *Indian J Med Res* 2017; 145: 693–696.
- Arun Babu, T, Vijayadevagar, V, Ananthakrishnan, S. Characteristics of pediatric scrub typhus eschar in South Indian children. *Pediatr Dermatol* 2017; 34: 124–127.
- Squires JE and William F. Balistreri. Manifestation of liver diseases. In: Kliegman RM (ed.) Nelson textbook of paediatrics. Philadelphia: Elsevier, 2016, p. 1922.
- Reade, MC, Weissfeld, L, Angus, DC, et al. The prevalence of anemia and its association with 90-day mortality in hospitalized community-acquired pneumonia. *BMC Pulm Med* 2010; 10: 15–15.