

## LAPROSCOPIC MYOMECTOMY VERSUS OPEN MYOMECTOMY FOR UTERINE FIBROIDS

Dr. Suvarna Samir Bhopale

MBBS, DGO, FMAS(MUHS) FICMCH, Shree Sai Hospital, Maternity, Surgical, Child Care And Laparoscopy Center, Near Santoshi Mata Mandir, Damle Chowk, Akola.

**Article Info:** Received 21 October 2021; Accepted 19 December 2021

**DOI:** <https://doi.org/10.32553/ijmbs.v5i12.2364>

**Corresponding author:** Dr. Suvarna Samir Bhopale

**Conflict of interest:** No conflict of interest.

### Abstract

Fibroids are common benign tumours arising in the uterus. Myomectomy is the surgical treatment of choice for women with symptomatic fibroids who prefer or want uterine conservation. Myomectomy can be performed by laparoscopy or open myomectomy. Aim of study is to determine the benefits and harms of laparoscopic myomectomy compared with open myomectomy. It is a comparative study conducted over 1 year in Department of Obstetrics and Gynecology, GMC, Akola, Maharashtra. 50 patients were included in study who were having uterine fibroid. Subjects were explained about surgery as treatment. 30 subjects underwent Laparoscopic myomectomy and 20 subjects underwent open myomectomy. The clinical data of patients who underwent OM and LM was analyzed. The data recorded comprised patient demographic information and clinical characteristics including age, weight, type, and size of myoma and myomectomy indications; and perioperative data including estimation of blood loss, duration of surgery, complications, and length of hospital stay.

**Keywords:** Laparoscopic myomectomy (LM), open myomectomy (OM), uterine fibroid.

### Introduction

Fibroids (leiomyomas or myomas) are benign tumors that arise from smooth muscle cells. Fibroids are found commonly in the uterus and connective tissues. They constitute the most common benign tumors among women. The pathogenesis of fibroids is associated with multiple factors including ovarian steroid hormones, growth factors, smooth muscle injury, and genetic predispositions.[1] Uterine fibroids commonly occur in women of reproductive age with an estimated rate of 20%–40%.[2] Uterine leiomyoma can be classified as intramural, submucosal, or subserosal. Leiomyomas are commonly asymptomatic.

Approximately 25% of these patients have symptoms such as heavy uterine bleeding, pelvic pain, pelvic and urinary retention symptoms, and infertility and complications in pregnancy.[3] Treatment options for myoma include hysterectomy, myomectomy, uterine artery embolization, myolysis, and medical therapy.[4] Myomectomy can be performed by laparoscopy or open myomectomy. LM is a less invasive method with minimal complications, and it has been established in recent years.[5] The selection of patients for medical therapy, noninvasive procedures, or surgery depends on an assessment of the size, number, and position of myomas.[6] OM involves surgical removal of the fibroids through an incision in the abdominal wall, closure of the resulting uterine dead space, and reconstitution of the remaining uterus. Some studies have reported transfusion rates of up to 20% during OM.[7] Evidence suggests that LM is associated with reduced morbidity compared to OM.[9]

### Material and Methods

It is a comparative study conducted over 1 year in Department of Obstetrics and Gynecology, GMC, Akola, Maharashtra. 50 patients were included in study who were having uterine fibroid. They were informed about the study and written consent was taken. 30 subjects underwent Laparoscopic myomectomy and 20 subjects underwent open myomectomy.

### Myomectomy operative techniques

OM was performed using a standard procedure. An incision was made on the skin depending on the size, location, and expected difficulty. Myomas were enucleated after an incision was made on the uterus using myoma screw or manually. LM was performed through 3–4 ports. The telescopic port is the higher most usually in the umbilicus. The other 2 or 3 accessory trocars would be inserted sufficiently high enough to provide an easy approach to the myomas for the laparoscopic instruments. The uterus was always cannulated to allow correct exposure of the myomas and strong counter tractions during enucleation and suturing. Before incision of the uterus, vasopressin was injected into the planned uterus incision site for each fibroid to reduce bleeding, however, not in all cases. The myomas were morcellated intracorporeally inside an endobag and removed through the laparoscopic incision. Glyconate monofilament absorbable suture was used for skin closure for some cases. This was to ensure proper apposition and leaving no gap for

hematoma. The abdominal incision was closed after all of instruments used were completely removed.

#### MODI'S AQUADISSECTION TECHNIQUE [12]

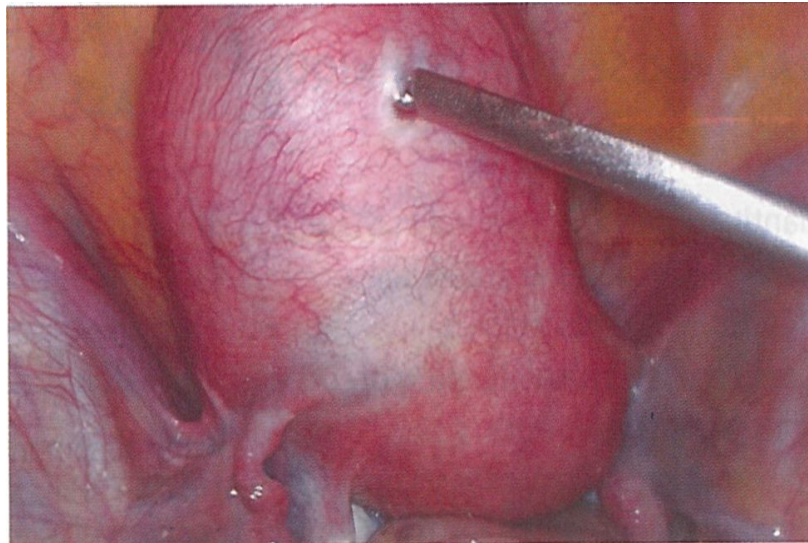
- Large quantity of saline is injected in the myometrium with a laparoscopic injection needle. This saline enters the myometrium and the blood in the myometrial tissue is replaced by saline.
- The vasopressin injected causes vasoconstriction of myometrial vessels which helps to hold the saline within the myometrium for a period of about 45-60 minutes.
- The saline and vasopressin solution follows the path of least resistance and enters the plane between the

myometrium and the myoma which helps in enucleation of myoma. Hence the name aquadissection.

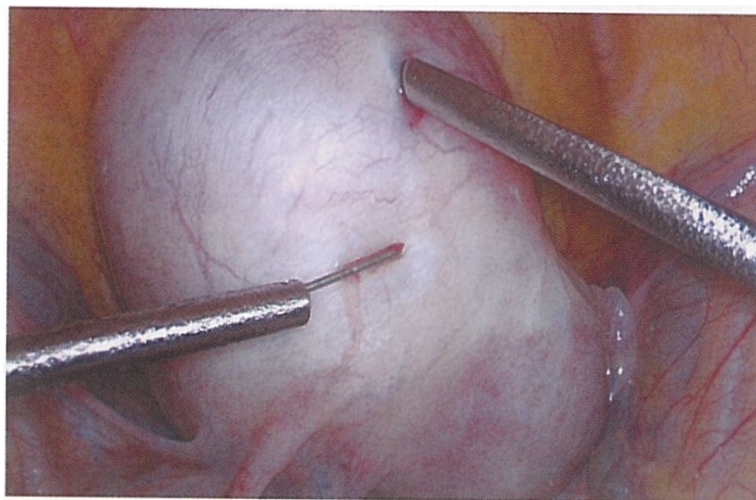
#### Technique

Vasopressin is diluted with saline as 10 unit of vasopressin for every 100 mL of saline. As the effect of aquadissection with saline and vasopressin is achieved, the color of uterus changes from pink to white or marble like appearance (Figs 1 to 5).

Incision is taken on the uterus with just a simple scissors (no energy\_source is required). Horizontal incision is preferred as it is easier to suture laparoscopically.

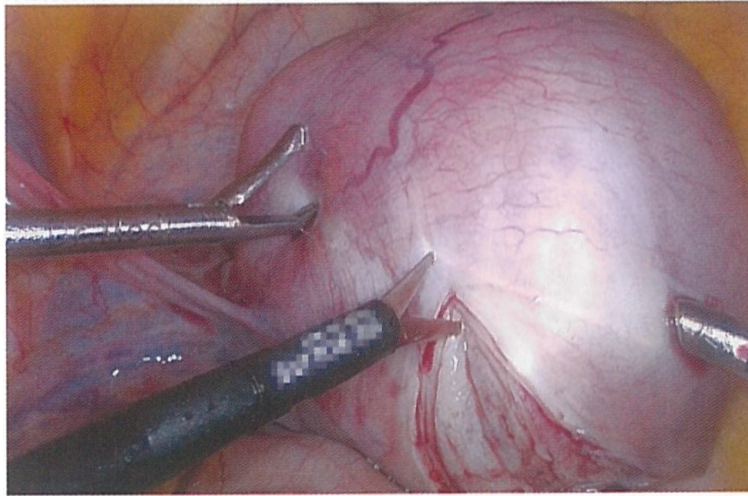


**Fig. 1: Myoma screw used for manipulation**

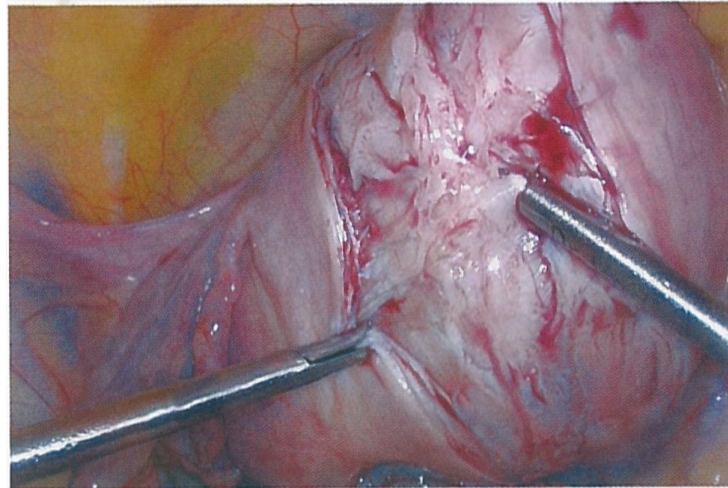


**Fig. 2: Marble white-appearance of uterus with aquadissection**

Vertical incision is more convenient in case any extension is required to be made for deep seated large fibroids. The separation of the fibroid is helped due to the dissection of the correct plane by the saline injection. Figs 6 to 8 For enucleation of the fibroid, traction



**Fig. 3: Only scissors used to cut the myometrium**



**Fig. 4: Avascular plane identified easily for fibroid separation**

is given with a myoma screw and counter traction given with aspiration cannula or a toothed needle holder. A lever action of the myoma screw to pull out the fibroid is more effective than directly pulling the myoma screw in line with the trocar. This prevents the avulsion or slipping of the myoma screw from the fibroid repeatedly (Figs 9 and 10).

Mainstay of hemostasis in laparoscopic myomectomy is suturing. Once the fibroid is separated, myometrium is sutured by barbed suture material (Figs 11 P to 13).

#### Advantages

- Myomectomy without energy source: Only a simple scissors is used to cut the myometrium. Neither a monopolar hook nor a harmonic is used. As no energy source is used for cutting or coagulation, no dead or scarred tissue is left behind. Thus there is better tissue healing, better scar integrity and less chances of scar dehiscence.
- Enucleation of myoma is easy as the saline and vasopressin solution partially dissects the myoma—myometrial interface.
- Chances of endometrial avulsion reduced in cases of intramural myomas; those with a submucosal component, the incidence of avulsion of endometrium are minimized.
- Reduced blood loss: usually 300-400 mL of blood loss may be seen during a myomectomy but with the use of aquadissection technique,
- Easy suturing of myometrial defect

#### Concerns

- The main concern with the use of vasopressin is that it causes sudden rise in blood pressure, if it is accidentally injected directly into a blood vessel. This complication can be avoided by simply aspirating before injecting.
- There are concerns regarding cardiac effect of vasopressin. Myocardial vessel constriction may mimic transient myocardial ischemia. This will manifest as ST segment depression on ECG monitoring. This may last for up to 20 min, till the effect of vasopressin wears off.
- If we only use 400 mL of saline without vasopressin then the effect of hemostasis will only be effective for 5-10

min during which time it is washed out from the tissues and bleeding starts while the surgery is still on.

## Results

A total of 50 women who underwent myomectomy were included in the analysis. 30 patients had undergone laparoscopic myomectomy and 20 patients had undergone

open myomectomy. All patients were divided into 2 groups as follows: those who underwent LM ( $n = 30$ ), OM ( $n = 20$ ). Table 1 shows number of patients with different types of fibroids. 25 patients had subserosal fibroid, 12 patients had intramural fibroid and 13 patients had submucosal fibroid.

**Table 1: Types of Uterine fibroids**

Type of fibroid	Number of patients
Subserosal	25
Intramural	12
Submucous	13

**Table 2: Size of uterine Fibroid and number of patients undergone LM/OM.**

Size of Fibroid	Number of subjects undergone LM(30)	Number of subjects undergone OM(20)
< 5 cm.	8	3
5 to 10 cm.	18	9
>10 cm.	4	8

It is also seen that patients undergoing OM had higher chances of postoperative infections as compared to patients undergoing LM.

**Table 3: Clinical parameters of Study subjects.**

Parameters	Number of subjects undergone LM(30)	Number of subjects undergone OM(20)	P value
Age(years)	35±3.42	33.02±4.34	>0.005
Duration of surgery(Minutes)	75±5.2	90±2.34	<0.005
Estimated blood loss(ml.)	120±15.34	250±20.34	<0.005
Hospital stay(days)	2±1	4±2	<0.005
Post operative infection	2±1	3±1	<0.005

<0.005 – highly significant.

## Discussion

All women who underwent myomectomy in this study had clinical symptoms such as menorrhagia, dysmenorrhea, abdominal mass, infertility and other symptoms which lead to reduced quality of life. This study revealed that morbidity outcomes were less in patients who underwent Laparoscopic myomectomy as compared to patients who underwent open myomectomy. There were differences in fibroid characteristics, blood loss, duration of hospital stay, and postoperative complications. LM was commonly used to remove myoma as it has a better cosmetic result and faster recovery than the OM. The main factors in employing LM are as follows: size of the fibroid, number of fibroids, the ability to secure hemostasis by laparoscopy, the removal of large fibroids out of the abdomen, the repair of the uterine incision, and the control of operative blood loss. Our morbidity analysis in this study favored LM in terms of blood loss, short duration of hospital stay, and less postoperative complications. [10,11] More than 50% of women who underwent LM reported no postoperative complications. Furthermore, our gynaecologists have been well trained in laparoscopic surgical skills. Careful preoperative selection for LM and OM will eventually reduce laparotomy conversion rate

in patients who undergo myomectomy, thereby reducing the duration of surgery and hospital stay.

## Conclusion

Our study showed both LM and OM are safe and reliable surgical methods with distinct surgical indications and outcomes. LM has several advantages over OM such as faster recovery and minimal risk; Preoperative evaluation of the size and number of myomas is necessary for careful selection of the patients to prevent laparotomy conversion and to reduce the intraoperative and postoperative complications. Laparoscopic myomectomy is a procedure associated with less subjectively reported postoperative pain, lower postoperative fever and shorter hospital stay compared with all types of open myomectomy. No evidence suggested a difference in recurrence risk between laparoscopic and open myomectomy.

## References

1. Lumsden MA. Embolization versus myomectomy versus hysterectomy: Which is best, when? *Hum Reprod* 2002;17:253-9.
2. Ryan GL, Syrop CH, Van Voorhis BJ. Role, epidemiology, and natural history of benign uterine mass lesions. *Clin Obstet Gynecol* 2005;48:312-24.

3. Wallach EE, Vlahos NF. Uterine myomas: An overview of development, clinical features, and management. *Obstet Gynecol* 2004;104:393-406.
4. Evans P, Brunzell S. Uterine fibroid tumors: Diagnosis and treatment. *Am Fam Physician* 2007;75:1503-8.
5. Holzer A, Jirecek ST, Illievich UM, Huber J, Wenzl RJ. Laparoscopic versus open myomectomy: A double-blind study to evaluate postoperative pain. *Anesth Analg* 2006;102:1480-4.
6. Khan AT, Shehmar M, Gupta JK. Uterine fibroids: Current perspectives. *Int J Womens Health* 2014;6:95-114.
7. LaMorte AI, Lalwani S, Diamond MP. Morbidity associated with abdominal myomectomy. *Obstet Gynecol* 1993;82:897-900.
8. Semm K. New methods of pelviscopy (gynecologic laparoscopy) for myomectomy, ovariectomy, tubectomy and adnectomy. *Endoscopy* 1979;11:85-93.
9. Jin C, Hu Y, Chen XC, Zheng FY, Lin F, Zhou K, *et al.* Laparoscopic versus open myomectomy – A metaanalysis of randomized controlled trials. *Eur J Obstet Gynecol Reprod Biol* 2009;145:121.
10. Marret H, Chevillot M, Giraudeau B; Study Group of the French Society of Gynaecology and Obstetrics (Ouest Division). A retrospective multicentre study comparing myomectomy by laparoscopy and laparotomy in current surgical practice. What are the best patient selection criteria? *Eur J Obstet Gynecol Reprod Biol* 2004;117:826.
11. Dubuisson JB, Fauconnier A, Fourchette V, Babaki-Fard K, Coste J, Chapron C. Laparoscopic myomectomy: Predicting the risk of conversion to an open procedure. *Hum Reprod* 2001;16:17231.
12. Modi Rajesh, AEC, Laparoscopic Myomectomy with Aquadissection and Barbed Sutures. 59<sup>th</sup> ACOG 2016. 117.