

Prevalence of Plate Exposure after Mandibular Resection in Ameloblastoma Patients

Erza Kurniawan¹, Winarno Priyanto², Abel Tasman Yuza³

¹Post Graduate Student of Oral and Maxillofacial Surgery Specialist, Universitas Padjajaran

²Staff of Oral and Maxillofacial Department, RSUP Dr. Hasan Sadikin

³Staff of Oral and Maxillofacial Department, Universitas Padjajaran

Article Info: Received 10 August 2022; Accepted 20 October 2022

doi: <https://doi.org/10.32553/ijmbs.v6i10.2612>

Corresponding author: Erza Kurniawan

Conflict of interest: No conflict of interest.

Abstract

Mandibular resection is a procedure to treat diseases or disorders of the mandible. Mandibulectomy is indicated for diseases involving the mandible. Plate exposure is a common postoperative complication of mandibular resection followed by reconstruction with plate fixation.

Objective: This study was to obtain data regarding the number of plate exposed cases after mandibular resection for indications of ameloblastoma at KSM Oral and Maxillofacial Surgery, RSUP Dr. Hasan Sadikin Bandung in the period January 2016 – December 2020.

Methods: This study is a descriptive study using medical record data of patients diagnosed as ameloblastoma. The variables studied included age, gender, time of exposure, plate length, number of screws.

Results: From the results of data collection for the last 3 years (2019-2021) at the Oral and Maxillofacial Surgery Section of Hasan Sadikin Hospital Bandung, it was found that the number of patients who underwent mandibular resection procedures in ameloblastoma cases was 25 patients. The patients consisted of 10 males and 15 females. AO plates were used as reconstruction material in 25 cases. Of the 25 cases, the exposure plate was found in 6 cases. Plate exposure occurs 4 years after resection in some cases. Of the 6 patients, 6 patients had plate removal.

Conclusion: Complications of plate exposure occur due to several factors such as age, plate length, and lack of adaptation of the plate. We must make a good plan of care during the preoperative period, by optimizing the condition of the patient before surgery to make a plan for proper plate placement, shaping and adjusting the shape of the plate, and estimating the need for graft placement.

Keywords: plate exposure, resection, Ameloblastoma.

Introduction

Mandibular resection is a procedure to treat mandibular diseases or disorders.¹ Mandibulectomy is indicated for diseases involving the mandible. This procedure can be carried out in various settings, including causes of infection (e.g., osteomyelitis), osteoradionecrosis, benign (e.g., ameloblastoma), or malignant neoplastic process (e.g., invasive squamous cell carcinoma) that involves the jaws.² Mandibular

discontinuity due to mandibular resection led to a loss of facial balance and symmetry. The mandible has a primary role in function and aesthetics. A loss of mandibular continuity disrupts the jaws' integrity and highly affects patients' self-perception and self-confidence.

Mandibular reconstruction aims to close primary wounds, repair phonation and deglutition, and aesthetic recovery in the lower part of the face.

Many techniques are available for mandibular reconstruction, such as free flap for soft tissue, reconstruction plate, and bone graft.⁴ Mandibular reconstruction plate is one of the reconstruction resection procedures often conducted in Hasan Sadikin Hospital.

Complications such as infection, plate exposure or fracture, or loosening of fixation can occur after this procedure. This article aims to detect risk factors of plate exposure after reconstruction plate fixation after mandibular resection in Hasan Sadikin Bandung.

In the last 3 years (2016-2018), data in the Department of Oral and Maxillofacial Surgery in Hasan Sadikin Hospital Bandung indicated 72 patients who underwent jaw resection procedures. The patients consist of 25 men and 47 women with an age range of 13-74 years old (average 38 years old). The diagnoses were different, with 7 and 65 patients with malignancy and benign diagnoses, respectively. AO plate was used as the reconstruction material in 72 cases.

Complications related to plate after surgery and screw plate including infection, wound dehiscence, plate exposure, loosening, damage to the screw, and plate fracture can occur. Plate exposure is a common post-surgical complication in mandibular resection followed by reconstruction with plate fixation.

Methods

This study is an analytical observation with a retrospective approach, using the data of plate exposure after mandibular resection in patients

diagnosed with ameloblastoma in Hasan Sadikin General Hospital Bandung.

The target population is the population that becomes the final target for the implementation of study results. The target population in this study was all plate exposure after mandibular resection cases in patients diagnosed with ameloblastoma in Dr. Hasan Sadikin General Hospital Bandung. The accessible population is a part of the target population that can be reached by the researchers. The accessible population in this study was ameloblastoma patients with plate exposure after mandibular resection between January 2019 – December 2021 in the Department of Oral and Maxillofacial Surgery of Dr. Hasan Sadikin General Hospital.

The study used data from medical records of ameloblastoma patients with plate exposure after mandibular resection in the Oral and Maxillofacial Surgery Department of Hasan Sadikin General Hospital. The study was conducted after obtaining ethical clearance from the Research Ethics Committee of UNPAD Faculty of Medicine/Hasan Sadikin General Hospital.

Results

The results of data collection from the Department of Oral and Maxillofacial Surgery of RSHS from January 2019-December 2021 obtained 25 ameloblastoma patients who underwent mandibular resection. The data described that the 25 patients were divided into 10 men (40%) and 15 women (60%).

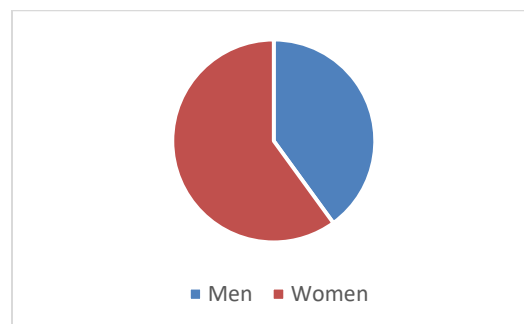


Figure 5: Gender prevalence in ameloblastoma

The figure showed that the majority of ameloblastoma patients were aged < 45 years and > 55 years, which consisted of 3 patients (50%), while there was 1 patient (2.7%) aged 0-10 years old. The incidence of ameloblastoma in Indonesia occurs between 37-50 years old.

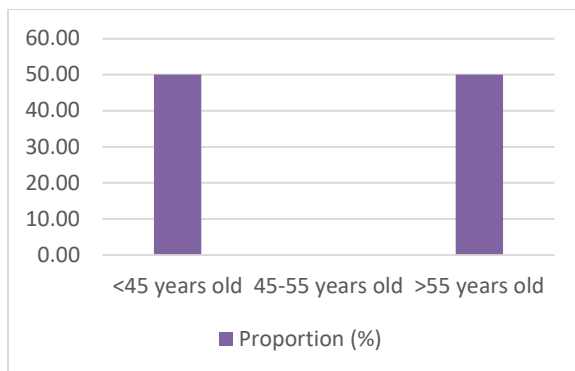


Figure 7: Age prevalence of plate exposure patients

Table 4.1: Plate length, screw length, and number

No	Patient	Treatment	Hole	Screw length	Screw number
1	DA	Post-segmental resection	17	10	8
2	TE	Post-hemimandibulectomy	14	10	4
3	T	Post-segmental resection	15	10	4
4	LD	Post-segmental resection	16	10	6
5	IJ	Post-segmental resection	12	10	3
6	AH	Post-segmental resection	16	10	5

According to the data, plate length and screws used varied. The longest plate was 17 holes, while the shortest was 12 holes, depending on the mass. The length of the screws used was 10mm.

The timing of plate exposure after mandibular resection in ameloblastoma patients varied. The graph showed that the timing of plate exposure frequently occurred four years after mandibular resection.

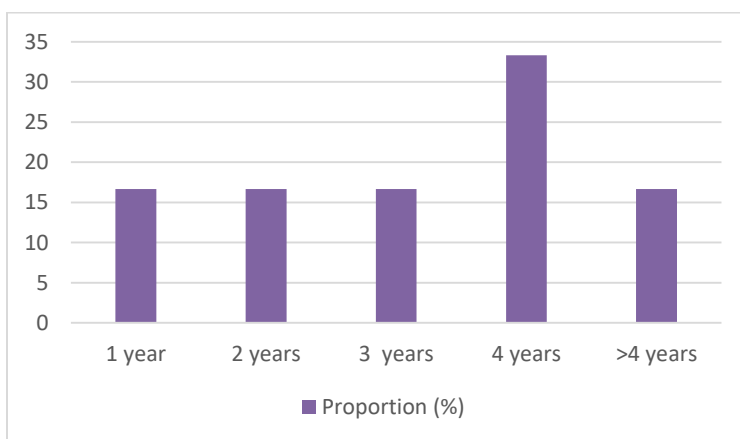


Figure 8: Timing of plate exposure

Discussion

The success rate of mandibular reconstruction has increased as a result of the advancement in plate design and material. However, complications of plate exposure after mandibular reconstruction with plate fixation still occur often. There are several factors related to plate exposure. In this study, we examined the variables of plate length, screw size, and number as factors related to plate exposure. Although no significance was found in plate exposure, the significance of these risk factors can not be neglected, considering the biological factor where these factors can affect wound healing. Excision extension is another potential factor that might be related to plate exposure. Nevertheless, we have not discussed excision extension in detail in this study. Previous studies also found a significant correlation between the existence of grafts with plate exposure. Several studies also stated that excision area, malignancy diagnosis, and the thickness of soft tissues covering the plate had a significant correlation with plate exposure.

Many factors might contribute to the exposure of the plate used for primary mandibular reconstruction after mandibular resection. Persistent dead space leads to pressure on the skin covering the plate surface during healing and creates a scar in the wound site. Thin soft tissues overlying the plate surface can cause physical irritation and skin compression to the plate which may contribute to plate exposure. The imbalance of soft tissue overlying the plate surface and the shape of the plate can cause the bulging part from the plate to press the overlying soft tissue and contribute to plate exposure. The area of mandibular resection that covers the midsegment of the mandible can lead to plate exposure. Meanwhile, plate exposure rarely occurs when the resection is limited to the lateral segment.

Conclusion

Based on the data from the last three years (2019-2021) in the Department of Oral and Maxillofacial Surgery of Hasan Sadikin Hospital

Bandung, 25 ameloblastoma patients underwent mandibular resection and 6 of them experienced plate exposure. The complication of plate exposure occurs because of several factors, such as age, plate length, and lack of plate adaptation. We must make appropriate treatment planning during the preoperative period by optimizing the patient's condition before the surgery to plan the proper plate placement, form and adjust plate shape, and consider the need for graft.

Reference:

1. Nalabolu GRK, Mohiddin A, Hiremath SKS, et al. Epidemiological Study of Odontogenic Tumours : An Institutional Experience. *Journal of Infection and Public Health*.2017; 10 : 324 - 330
2. Andersson L, Khanberg KE, Pogrel MA. *Oral and Maxillofacial Surgery*. 2010. ed-1; 32:629-728. United Kingdom : Blackwell Publishing
3. Fonseca RJ, Carlson ER, Ness GM. *Oral and Maxillofacial Surgery*. 2018. ed-3 (2) : 301.481. Missouri : Elsevier.
4. Ruslin, M. Hendra FN. Vojdani A, et al. The Epidemiology, Treatment, and Complication of Ameloblastoma in East Indonesia : 6 years retrospective surgery. *Med Oral Patol Oral Cir Bucal*. 2018. Jan 1;23 (1):e54-8.
5. Lumerman HS, Bowe RB. 2012. *Atlas of Oral and Maxillofacial Histopathology*. ed-2; 2: 21-60. Philadelphia : Walters Kluwer Health.
6. Aramanadka C, Kamath AT, Kudva A. Recurrent Ameloblastoma: A Surgical Challenge. *Hindawi : Case Reports in Dentistry*. 2018 : 1-6
7. Mc Clary AC. West RB. Pollack JR. et al. Ameloblastoma: a clinical review and trends in management. *Eur Arch Otorhinolaryngol*. 2016 : 1-13
8. Effiom OA, Ogundana OM, Akinshipo AO, Akintoye SO. Ameloblastoma : current etiopathological concepts and management. *Oral Diseases* (2018) 24, 307–316

9. Masthan KMK, Anitha N, Krupaa J, et al. Ameloblastoma. *J Pharm Bioallied Sci.* 2015 Apr; 7(Suppl 1): S167–S170
10. Jeddy N, Jeyapradha T, Ananthalakshmi R, Jeeva S, Saikrishna P, Lakshmipathy P. The molecular and genetic aspects in the pathogenesis and treatment of ameloblastoma. *J Dr NTR Univ Health Sci.* 2013;2:157–61.
11. Koong B. 2017. *Atlas of Oral and Maxillofacial Radiology.* ed-1; 10: 153-178 United Kingdom : John Wiley & Sons Ltd.
12. Sasaki R, Watanabe Y, Ando T, et al. Two Stage Enucleation and Deflation of a Large Unicystic Ameloblastoma with Mural Invasion in Mandible. *Craniofacial Trauma Reconstruction.* 2014;7:139–142
13. Barbosa GL, Oliveira ML, Almeida SM, et al. Computed Tomography Imaging Features of Multicystic Granular Cell Ameloblastoma : A Case Report. *Stomatos,* Vol. 20, 39, Jul-Dec. 2014
14. Beena VT, Choudhary K, Heera R, et al. Peripheral Ameloblastoma : A Case Report and Review Literature. Hindawi Publishing Corporation. 2012;1 -4
15. Neville DW, Damm DD, Allen CM, Chi AC. 2016. *Oral and Maxillofacial Pathology.* ed-4; 15 : 653-668. Missouri : Elsevier
16. Sadat S, Ahmed M. “Dredging Method”- A Conservative Surgical Approach for the treatment of Ameloblastoma Jaw. *Journal of Bangladesh College of Physicians and Surgeons.* Vol 29. No.2. 2011
17. Au SW, Li KY, Choi WS, et al. Risk factors for recurrence of ameloblastoma : a long-term follow up retrospective study. *Int. J. Oral Maxillofac. Surg.* 2019; 7 : 1-7
18. Wright JM, Tekkesin MS. Odontogenic tumors: where are we in 2017. *J Istanbul Univ Fac Dent* 2017;51:10–30.
19. Chichua N, Pai S, Gigineishvili E, Sharashenidze M. Management of Ameloblastoma : Desirable Treatment Approach. *Caucasus Journal of Health Science and Public Health.* Vol 1. 2016
20. Gunawardane S R, Attygalla A M. The Dredging Method: an Alternative Technique for Conservative Management of Ameloblastoma. A Case Report. *Sri Lanka Dental Journal* 2017; 47(02) 23-27. 2017
21. Malhiero P., Feio L., Costa H., Unicystic Plexiform Ameloblastoma: Case Report. *Revista De Saude Amato Lusitano* 2013; 32, p. 54
22. Santis GD, Cordeiro PG, Chiarini L. 2019. *Atlas of Mandibular and Maxillary Reconstruction with The Fibula Flap : A step-by-step approach.* ed-1;2 : 3-12. Switzerland : Springer
23. Saghravanian N, Salehinejad J, Ghazi N, Shirdel M, Razi M. A 40-year retrospective clinicopathological study of ameloblastoma in Iran. *Asian Pac J Cancer Prev.* 2016;17:619–23
24. Rusdiana, Rusdiana, et al. "Profile of ameloblastoma from a retrospective study in Jakarta, Indonesia." *Journal of Dentistry Indonesia* 18.2 (2011): 27-32.