

Hepatoprotective Effect of Herbal Medicinal Plant Extract against Paracetamol Induced Liver Injury in Rats

Pawan Sharma^{*1}, Vinod Nakra², Vidhi Jain³, Manmeet Singh Saluja⁴

¹Research Scholars, Department of Pharmacy, SunRise University, Alwar, Rajasthan.

²Professor, Department of Pharmacy, SunRise University, Alwar, Rajasthan.

³Professor & Principal, Maa Vaisnavi Education Institute & Research Sansthan, Baran, Rajasthan.

⁴Professor, Department of Pharmacology, Saint Solider College of Pharmacy, Tonk, Rajasthan.

Received: 15-02-2023 / Revised: 28-02-2023 / Accepted: 23-03-2023

DOI: <https://doi.org/10.32553/ijmbs.v7i4.2689>

Corresponding author: Pawan Sharma

Conflict of interest: No conflict of interest.

Abstract

The purpose of this study was to examine the hepatoprotective efficacy of *Whole plant extract of Adiantum capillus* against Paracetamol induced liver damage in rats. Wistar albino rats were orally fed 500 mg/kg of body weight of Methanolic and Acetonic *extract of Adiantum capillus Whole plant*, with Silymarin serving as the reference. By restoring functional parameters, physical parameters, biochemical parameters, and decreasing blood enzymes alkaline phosphatase (ALP) and total bilirubin (TBL) in the selected animal, the methanolic and Acetonic extracts exhibited a potent hepatoprotective effect. The plant's chemical composition includes, among others, alkaloids, flavonoids, glycosides, steroids, terpenoids, phenolics, and saponins. The overall experimental data suggest that bioactive phytoconstituents, such as flavonoids and alkaloids, present in the Methanolic and Acetonic extracts of *Adiantum capillus plant* may be responsible for the plant's significant hepatoprotective effect. The results thus support the use of *Adiantum capillus plant* as a hepatoprotectant.

Keywords

Carbon tetrachloride, Hepatoprotective activity, *Adiantum capillus plant*.

Introduction

Adiantum capillus-veneris Linn. (Adiantaceae) is a medicinal, delicate graceful fern, small, rhizomatous, ornamental, erect and perennial herb up to 30 cm tall with long polished black stripes widely distributed throughout the world. Ethnomedicinally, the genus is important and popularly known as “Hansraj” in Ayurvedic System of medicine and regular names are avenca and maidenhair plant. Hansraj is the native plant of America but also grows all over the world. It grows in moist and shady places. In India, it grows in the western Himalayas and extending up to Manipur. It also grows in Punjab, Bihar, Maharashtra, South India, Dalhousie Kashmir, Nainital, Shimla, and Mussorie. It is rarely found

in Afghanistan and Baluchistan way to Arabia, Siberia, Southern and Central Europe, Ireland and south west England. Here, we evaluated the ability of methanolic and Acetonic extract of *Adiantum capillus plant* to prevent or minimize the severity of Paracetamol induced liver damage in rats. [1-14]

Procurement and Authentication of the Plant

The *Adiantum capillus plant* were collected from the area around Alwar, Rajasthan, and then submitted to the Department of Botany at Sunrise University, Alwar, Rajasthan, where they were authenticated.

Preparation of extracts of *Adiantum capillus*

In order to increase polarity, 500g of powdered *Adiantum capillus* plant were extracted using a Soxhlet device and a solvent. By means of evaporation, the materials were concentrated [15].

Animals

The Central Drug Research Institute in Lucknow, India, supplied 150-200 g Wistar albino rats. The animals were given a normal pellet diet (Hindustan lever Ltd., Bangalore) and had access to drink at will. Each animal was acclimated for one week prior to usage. After examination, the Institutional Animal Ethics Committee authorized the experimental procedures. The medication was administered to the animals using an oral gavage tube. All animals were cared for ethically in accordance with CPCSEA norms, and rats were subjected to frequent inspections. The laboratory settings are supervised by a licensed veterinarian [16].

Chemicals

All chemical and solvent was of analytical quality. Micro Lbs in Goa, India, provided a complimentary sample of silymarin. India's Span Diagnostics Ltd. supplied standard kits for SGOT, SGPT, ALP, and others.

Preliminary phytochemical analysis

An initial phytochemical analysis was conducted to establish which phytoconstituents were present in each extract.

Toxicity studies

According to the OECD 423 guidelines [16], all of the extracts were submitted to an acute toxicity test. Albino female rats were used for research into acute toxicity. Before giving the extract orally at doses of 100, 200, and 500mg/kg bw, the animals were fasted for 24 hours with just water and then observed for up to 72 hours for toxic signs. All extracts had a therapeutic oral dose of 500 mg/kg body weight.

Paracetamol induced hepatotoxicity

The rats, of both sexes, were split up into 6 groups of six each. (n = 6) [16, 17]

- Group I (Control): administered water (5 mililitre/kilogram, p.o.) o.d. for nine days.
- Group II (-ve control): administered water (5 mililitre/kilogram, p.o.) o.d. for nine days, meanwhile on the seventh day, paracetamol (1 g/kg p.o.) was administered.
- Group III (+ve control): administered the normal medicine silymarin (25 mg/kg, p.o.) o.d. for nine days, meanwhile on the seventh day, paracetamol (1 g/kg p.o.) was administered.
- Group IV and V (Test Sample) administered The Methanolic (MEAC) & Acetonic (AEAC) (500 mg/kg) extract of *Adiantum capillus* plant o.d. for nine days, meanwhile on the seventh day, paracetamol (1 g/kg p.o.) was administered.

Blood was collected from animals on the last day by puncturing the retro orbital plexus. Blood samples were allowed to clot at room temperature for 45 minutes. SGOT & SGPT [18], ALP [19], serum bilirubin [20], and serum protein [21] were measured after serum was separated by centrifugation at 2500 rpm at 30°C for 15 minutes and used for the assessment of different biochemical parameters. After the collection of blood samples, the animals were sacrificed while deeply sedated with ether. In evaluating the drug's preventive impact, morphological data such as animal weight and liver weight have also been considered. The hepatoprotective chemical decreases the liver weight per 100 g of rat body weight [22, 23].

Histopathology studies

In each group of animals, a small piece of liver tissue was removed and washed in normal saline. The liver tissues were paraffin embedded after being fixed in 10% buffered neutral formalin for 48 hours and then in bovine solution for 6 hours. Staining with hematoxylin and eosin was performed on slices that were 5 mm thick and cut using a microtome. These slices were looked at

using a light microscope at a magnification of 100X [24].

Statistical Significance

The results of the study were expressed as mean \pm SEM, n=6. ANOVA [25] was used to analyze and compare the data, followed by Dunnet's [26] test for multiple comparisons.

Results

The phytoconstituents in the various extracts were detected using chemical analysis. Results show that the highest concentrations of pharmacologically active chemicals, including glycosides, sponins, phytosterols, and flavonoids, are found in the Methanolic (MEAC) and Acetonic (AEAC) extract of *Adiantum capillus* plant. In light of this, the pharmacological studies choose to focus on these extracts. Table 1 displays the results. At a dosage of 5000 mg/kg, there was no toxicity or behavioural alterations seen in the animal groups that were subjected to the graduated dose. This result indicates that 500 mg/kg, p.o. of Methanolic (MEAC) & Acetonic (AEAC) extracts of *Adiantum capillus* plant were safe or non-toxic to rats. After receiving a thiopentone sodium (40 mg/kg) intramuscular injection, all test groups exhibited sleepiness. Rats given Paracetamol slept for longer periods

overall and had considerably later sleep onset times (measured in minutes). Methanolic (MEAC) and Acetonic (AEAC) whole plant extract of *Adiantum capillus* (500 mg/kg, p.o.) and silymarin significantly enhanced sleep start but significantly decreased sleep duration in rats compared to a Paracetamol treatment group. The results are shown in Table 2. Both the weight and volume of the livers of those who were given, Paracetamol showed growth, suggesting that the livers of those people had enlarged. Whole plant extract of *Adiantum capillus* ie., (MEAC) and Acetonic extract (AEAC) (500 mg/kg, p.o.) substantially recovered liver weight compared to the control group. The results are shown in Table 3. Pretreatment with Methanolic (MEAC) & Acetonic (AEAC) extract of *Adiantum capillus* plant (500 mg/kg, p.o.) and silymarin (25 mg/kg, p.o.) showed a capacity to prevent the hepatotoxicity by reducing serum marker enzymes. Findings are shown in Table 4. An elevation in total bilirubin and a decrease in total protein content were observed in Paracetamol-treated groups. Total bilirubin was significantly decreased and total protein was significantly increased after pretreatment with a Methanolic (MEAC) and Acetonic (AEAC) extract of *Adiantum capillus* plant (500 mg/kg, p.o.) Outcomes are shown in Table 4.

Table 1: Preliminary Phytochemical studies of Extracts of *Adiantum capillus* plant extract Stem

Constituents	Methanolic Extract (MEAC)	Acetonic Extract (MEAC)
Carbohydrate	- ve	+ ve
Glycosides	- ve	- ve
Oil and fats	+ ve	+ ve
Proteins	+ ve	+ ve
Saponins	- ve	- ve
Phenolic comp. and tannins	+ ve	+ ve
Phytosterols	+ ve	+ ve
Alkaloids	+ ve	+ ve
Gums and mucilage	+ ve	+ ve
Flavonoids	+ ve	+ ve

Table 2: Effect of Methanolic (MEAC) & Acetonic (AEAC) extract of *Adiantum capillus plant* on functional parameters in Paracetamol induced hepatotoxic rats.

Treatment/ Dose	Onset of sleep(Sec.)	Duration of sleep (Min.)
Normal	168.4 ± 2.22	1.54 ± 1.49
Paracetamol	225.4 ± 5.44*	248.3 ± 5.62*
Silymarin	174.51 ± 3.22***	170.5 ± 5.28***
MEAC (500 mg/kg)	195.71 ± 5.54***	189.72 ± 5.61***
AEAC (500 mg/kg)	185.52 ± 4.55**	182.0 ± 4.12**

Values are mean ± SEM, n = 6. (One way ANOVA Followed by Dunnette multiple comparisons test). Statistically significance of ** P<0.01, *** P<0.001, when compared with **Paracetamol** induced group and * P<0.05, when compared with normal group.

Table 3: Effect of Methanolic (MEAC) & Acetonic (AEAC) extract of *Adiantum capillus plant* on Physical Parameters in Paracetamol induced hepatotoxic rats.

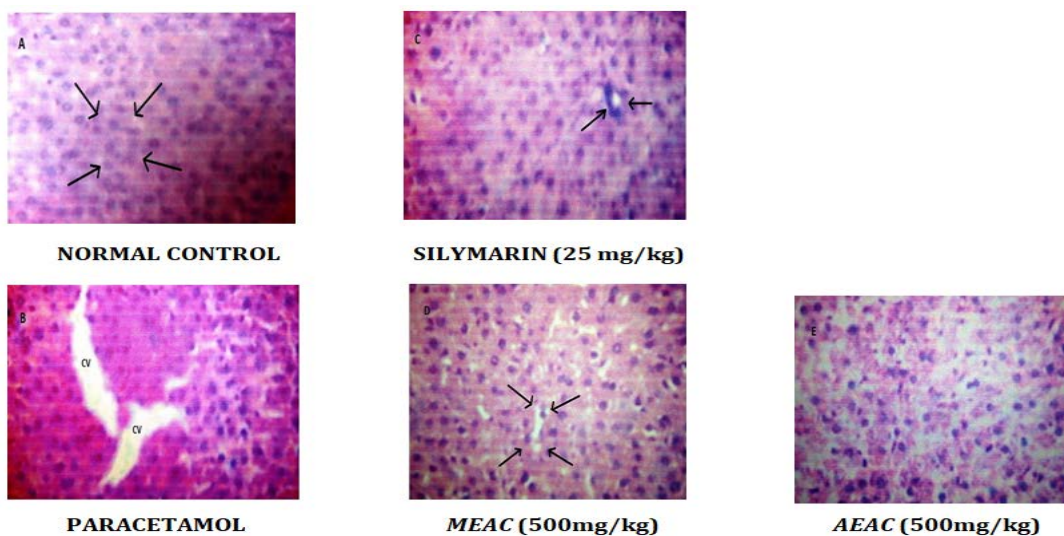
Treatment/ Dose	Liver Weight	Liver Volume
Normal	7.51 ± 0.04	7.85 ± 0.06
Paracetamol	11.08 ± 0.54*	11.24 ± 0.52*
Silymarin	7.78 ± 0.55***	7.81 ± 0.69***
MEAC (500 mg/kg)	7.94 ± 0.75***	7.98 ± 0.98***
AEAC (500 mg/kg)	7.89 ± 0.58***	7.98 ± 1.44**

Values are mean ± SEM, n = 6. (One way ANOVA Followed by Dunnette multiple comparisons test). Statistically significance of ** P<0.01, *** P<0.001, when compared with **Paracetamol** induced group and * P<0.05, when compared with normal group.

Table 4: Effect of Methanolic (MEAC) & Acetonic (AEAC) extract of *Adiantum capillus plant* on serum enzyme parameter in Paracetamol induced hepatotoxic rats.

Treatment/ Dose	SGPT U/L	SGOT U/L	ALP U/L	Total Bilirubin (mg/dl)	Total Protein (gm/dl)
Normal	165.1 ± 3.54	169.05 ± 2.68	185.0 ± 8.12	1.68 ± 0.04	6.65 ± 0.34
Paracetamol	194.42 ± 6.53*	267.69 ± 7.44*	287.22 ± 6.75*	5.67 ± 4.08*	8.79 ± 0.26*
Silymarin	171.45 ± 3.52***	178.58 ± 5.44***	192.74 ± 7.44***	1.72 ± 3.57***	7.25 ± 3.44***
MEAC (500 mg/kg)	181.25 ± 5.81***	266.04 ± 9.46***	211.32 ± 8.46***	1.92 ± 0.48***	8.11 ± 1.24***
AEAC (500 mg/kg)	178.12 ± 3.75***	184.11 ± 4.43***	194.14 ± 8.41***	1.76 ± 4.43***	7.41 ± 3.24**

Values are mean ± SEM, n = 6. (One way ANOVA Followed by Dunnette multiple comparisons test). Statistically significance of ** P<0.01, *** P<0.001, when compared with **Paracetamol** induced group and * P<0.05, when compared with normal group.



Effect of *Adiantum Capillus Plant* on Histopathological Diagram of Liver Tissue in Paracetamol induced Hepatotoxic Rats.

Discussion

Many variables, such as chemicals and medicines, may cause liver damage or injury. Because it is clinically relevant, **Paracetamol** was employed to produce hepatotoxicity in this investigation. Elevated levels of serum glutamic oxaloacetic transaminase (SGOT) and serum glutamic pyruvic transaminase (SGPT) are indicators of hepatocellular damage [27].

Paracetamol is a common antipyretic and analgesic. Several research in animals and people have shown that greater dosages of acetaminophen cause liver damage. Paracetamol-induced hepatotoxicity has been utilized as a reliable approach for screening Hepatoprotective drugs. Paracetamol is largely metabolized in the liver and excreted by the kidney after conjugation with sulphate and glucuronide. Furthermore, paracetamol hepatotoxicity has been linked to the creation of hazardous metabolites when a portion of the drug is converted by hepatic cytochrome P-450 to the highly reactive metabolite N acetyl-p-benzoquinoneimine (NAPQI). Toxic metabolites (N-acetyl-p-benzoquinoneimine) have the ability to alkylate and oxidize intracellular GSH, resulting in liver damage. GSH depletion causes enhanced lipid peroxidation by extracting hydrogen from a

polyunsaturated fatty acid and, eventually, liver injury owing to larger paracetamol dosages. Reactive metabolites may cause early cell stress by a variety of methods, including glutathione (GSH) depletion or binding to enzymes, lipids, nucleic acids, and other cell components. AST and ALP are normally seen in significant concentrations in the liver. These enzymes are released from the cells as a result of hepatocyte necrosis or aberrant membrane permeability, and their levels in the blood rise. ALT is a sensitive marker of acute liver injury, and its rise in non-hepatic illnesses is rare. ALT is a more specific hepatic paranchymal enzyme than AST. [28].

The administration of paracetamol to experimental animals resulted in a statistically significant increase in the levels of enzymes such as SGOT, SGPT, ACP, ALP, and others, suggesting chemical-induced liver injury. The inhibitory impact of *Adiantum capillus plant extract* i.e., Methanolic (MEAC) and Acetonic (AEAC) extracts (500 mg/kg, p.o.) on hepatotoxicity was compared to that of the positive control group. Pretreatment of the animals with *Methanolic (MEAC) & Acetonic (AEAC) extract of Adiantum capillus plant* (500 mg/kg, p.o.) provided considerable protection in

biochemical parameters such as SGOT, SGPT, ACP, and ALP against **Paracetamol**-induced increases. Furthermore, there was an increase in the weight of the liver treated with **Paracetamol** when compared to the control. The **Methanolic (MEAC) & Acetonic (AEAC) extract of *Adiantum capillus plant*** (500 mg/kg, p.o.) therapy keeps the liver weight close to normal. A control rat's liver segment reveals a normal hepatic architectural wall caused by the central vein. The liver samples of **Paracetamol**-treated rats showed gross necrosis of the centrilobular hepatocytes characterized by gross necrosis, degeneration, karyolysis, and eosinophilic infiltration, which was significantly prevented by treatment with the **Methanolic (MEAC) & Acetonic (AEAC) extract of *Adiantum capillus*** (500 mg/kg, p.o.) that demonstrated hepatoprotective activity. A number of scientific studies have shown that some flavonoids, triterpenoids, and steroids have antioxidant characteristics that protect the liver. Administration of **Methanolic (MEAC) & Acetonic (AEAC) extract of *Adiantum capillus*** (500 mg/kg, p.o.) that demonstrated significant hepatoprotective activity; while qualitative phytochemical investigations on the **Methanolic (MEAC) & Acetonic (AEAC) extract of *Adiantum capillus plant*** (500 mg/kg, p.o.) that demonstrated positive flavonoids by chemical tests. Furthermore, it has been observed that the plant's flavonoid contents have antioxidant qualities and have been proven to be effective in the treatment of liver damage. [29]

Treatment with hepatoprotective medications may help the liver's hepatocytes endure **Paracetamol**'s damaging effects. The findings showed that ***Adiantum capillus plant*** extract (500 mg/kg, p.o.) exhibits considerable hepatoprotective action when tested in methanolic (MEAC) and Acetonic (AEAC) solvents. The data showed that the hepatotoxic effects of Paracetamol were significantly reduced.

References

1. Singh SS, Pandey SC, Shrivastava S, et al. Chemistry and medicinal properties of ***Curcuma amada rhizome***. Indian J Pharmacol. 2003; 35: 83-9.
2. Kirtikar KR, Basu BD. Indian Medicinal Plants, Vol 1. 2nd ed. New Connaught Place, Dehra Dun; 1975.
3. Nayampalli SS, Ainapure SS, Samant BD, et al. A comparative study of diuretic effects of ***Adiantum capillus plant extract*** and hydrochloro-thiazide in rats and a preliminary phase I study in human volunteers. J Postgrad Med. 1988; 34: 233-6.
4. Aiyer KN, Kolammal M. Pharmacognosy of Ayurvedic Drugs, Series 1. 1st ed. Trivendram: The Central Research Institute; 1963.
5. Raghunathan K, Mittra R. Pharmacognosy of Indigenous Drugs. New Delhi: Central Council for Research In Ayurveda & Siddh; 1982.
6. Nadkarni KM, Nadkarni AK. Indian Materia Medica, Vol 1. 3rd ed. Mumbai: M/S Popular Prakasan Pvt. Ltd; 1976.
7. Zhao TF, Wang X, Rimando AM, et al. Folkloric medicinal plants: *Tinospora sagittata* var. *cravaniana* and *Mahonia bealei*. Planta Medica. 1991; 57: 505.
8. Dhaliwal KS. Method and composition for treatment of diabetes. US Patent 5886029; 1999.
9. Kapil A, Sharma S. Immunopotentiating compounds from ***Curcuma amada rhizome***. J Ethnopharmacol. 1997; 58: 89-95.
10. Mehrotra R, Katiyar CK, Gupta AP. Hepatoprotective compositions and composition for treatment of conditions related to hepatitis B and E infection. US Patent 749296; 2000.
11. Jana U, Chattopadhyay RN, Shw BP. Preliminary studies on anti-inflammaory activity of *Zingiber officinale* Rosc., *Vitex negundo* Linn. and ***Adiantum capillus plant***

- extract* (Willid) Miers in albino rats. Indian J Pharmacol. 1999; 31: 232-3.
12. Anonymous. Wealth of India: Raw materials, Vol X. New Delhi: CSIR; 1976.
 13. Sethuraman MG, Lalitha KG, Raj Kapoor B. Hepatoprotective activity of *Sarcostemma brevistigma* against carbon tetrachloride-induced hepatic damage in rats. Current Science. 2003; 84: 1186-87.
 14. Singh RP, Padmavathi B, Rao AR. Modulatory influence of *Adhatoda vesica* (*Justica adhatoda*) leaf extract on the enzyme of xenobiotic metabolism, antioxidant status and lipid peroxidation in mice. Mol Cell Biochem. 2000; 213: 99-109.
 15. Harbone JB. Phytochemical methods - A guide to modern technique of plant analysis, 2nd edn, Chapman and Hall, New York; 1984. 85pp.
 16. CPCSEA. (2003) Indian Journal pharmacology 35: 257-274.
 17. Ward FM and Daly MJ. (1999) "Hepatic Disease. In: Clinical Pharmacy and Therapeutics (Walker R. and C. Edwards Eds.)". Churchill Livingstone, New York. pp. 195-212.
 18. Yoganarasimhan SN. (1996) Medicinal plant of India. vol-1 Karnataka. Interline publishing pvt.ltd, Bangalore, pp 232.
 19. Reitman S, Frankel S. (1957) A colorimetric method for the determination of serum glutamic oxalacetic and glutamic pyruvic transaminases. American Journal Clinical Pathology 28: 56-63.
 20. Kind PRN, King EJ. (1954) Estimation of plasma phosphatase by determination of hydrolysed phenol with amino-antipyrine. Journal Clinical Pathology 7(4): 322-326.
 21. Amour FF D', Blood FR, Belden DA. (1965) The manual for laboratory work in Mammalian Physiology. The University of Chicago Press, Chicago, 126-128.
 22. Lowry OH, Rosebrough NJ, Farr AL, Randall RJ. (1951) Protein measurement with the Folin phenol reagent. Journal of Biological Chemistry 193: 265-275.
 23. Avadhoot V, Rana V. (1991) Hepatoprotective effect of *Vitex negundo* against carbon tetrachloride-induced liver damage. Arch Pharmacy Research 14(1): 96-98.
 24. Bhanwra V, Singh V, Khosla V. (2000) Effect of *Azadirachta indica* (Neem) leaf aqueous extract on paracetamol-induced liver damage in rats. Indian Journal of Physiology and Pharmacology 44(1): 64-68.
 25. Mankani KL, Krishna V, Manjunatha BK, Vidya SM, Singh SJ, Manohara YN, Raheman A, Avinash KR. (2005) A review of natural products with hepatoprotective Activity. Indian Journal of Pharmacology 37(3): 165-168.
 26. Gennaro AR. (1995) Remington: The science and practice of pharmacy, vol. I, 19th ed, Mack Publishing Company, Easton (PA), pp.111.
 27. Dunnet CW. (1964) New Tables for Multiple Comparisons with a Control. Biometrics 20: 482-491.
 28. Yue M, Yu CH, Ren K, Chen W, Li Y. (2006) Transient elevation of hepatic enzymes in volunteers after intake of alcohol. Hepatobiliary and Pancreatic Diseases International 5(1): 52-55.
 29. Zhou Z, Wang L, Song Z, Lambert JC, McClain CJ, Kang YJ. (2003) A critical involvement of oxidative stress in acute alcohol-induced hepatic TNF-alpha production. American Journal of Pathology 163: 1137-1146.