

Osteotomy Le fort I as a Treatment option for class III Dentoskeletal Problem

Khriztie Limanthara^{1*}, Seto Adiantoro Sadputranto², Abel Tasman Yuza³

^{1*}Resident Oral and Maxillofacial Surgery, Faculty of Dentistry, Universitas Padjadjaran / RSUP Dr. Hasan Sadikin Bandung, Indonesia

²Staff of The Department of Oral and Maxillofacial Surgery, RSUP Dr. Hasan Sadikin Bandung, Indonesia.

³Staff of The Department of Oral and Maxillofacial Surgery, Faculty of Dentistry, Universitas Padjadjaran, Indonesia

Received: 02-03-2024 / Revised: 29-03-2024 / Accepted: 15-04-2024

DOI: <https://doi.org/10.32553/ijmbs.v8i1.2779>

Corresponding author: Khriztie Limanthara

Conflict of interest: No conflict of interest.

Abstract

Introduction: Orthognathic surgery is surgery to correct the jaw relation and which aim to correct dentoskeletal deformities and a treatment option for severe deformity that cannot be corrected by orthodontic treatment alone. Le fort I osteotomy is a technique in orthognathic surgery that aims to correct the maxilla. In its management, it is possible for correction of the maxilla and mandible to achieve an optimal jaw relation, function and esthetics.

Case report: This case report explained a patient with maxilla retrognathism accompanied by function and aesthetic problems. This patient was diagnosed with class III dysgnathy and was performed orthognathic surgery treatment with le fort I osteotomy technique under general anesthesia at Central Operating Theater at Hasan Sadikin General Hospital, Bandung, and was evaluate periodically after the surgery. **Conclusion:** In this case, the patient's function and aesthetic problems was corrected without causing any postoperative complications. Careful planning with a good calculation and treatment plans are important for obtaining a good result.

Keywords: Le fort I osteotomy, class III disgnathy, dentoskeletal deformity

Introduction

Class III dysgnathia, also known as class III dentoskeletal malocclusion, is a type of malocclusion with class III dental and skeletal associations. It is defined as maxillary retrognathism and mandibular prognathism.¹ The etiology of the class III dentoskeletal malocclusion is influenced by the interaction of environmental and genetic factors.^{2,3} The prevalence of this kind of malocclusion varies by population, ranging from 0% to 26%, with countries in Southeast Asia

(China and Malaysia) showing the highest prevalence rate at 15.8%, the Middle East having an average prevalence rate of 10.2%, and European countries having a lower prevalence rate at 4.9%.⁴ Among the complaints brought due to this dentoskeletal malocclusion are those of impaired speech, mastication, and appearance. Children can experience craniofacial complaints such as mandibular immobility and TMJ dysfunction, and these complaints become more

common as people get older.⁵ Currently the treatments of choice for this condition are growth modification, camouflage treatment, and orthognathic surgery.⁶

Dentoskeletal abnormalities may be treated by orthognathic surgery. The maxilla and mandible are adjusted during the surgery to achieve the appropriate skeletal and dental relations and proportions. Class I occlusion relations, good function, and ideal aesthetics are the main objectives of this treatment.⁷

Orthognathic surgery is the treatment of choice for patients with skeletal malocclusions that cannot be corrected by orthodontic treatment alone. The benefit of this surgery is that it produces a measurable outcome with little trauma to important anatomical tissues.⁸ The techniques commonly used in orthognathic surgery include osteotomy le fort I, bilateral sagittal split osteotomy (BSSO), and osseous genioplasty.⁹

Le fort I osteotomy is commonly used to correct malocclusion and maxillary deformity. In order to correct the maxilla, a separation is formed on the hard tissue of the maxilla against the skull base. The maxilla can be repositioned anteriorly, posteriorly for a small degree, superiorly, and inferiorly during a Le Fort I osteotomy in order to correct class II and III malocclusions as well as dentofacial asymmetry. Le Fort I osteotomy procedure are frequently performed for Class III malocclusions with maxillary retrognathia.^{10,11}

This case report will describe a class III dentoskeletal malocclusion that occurred in a 23-year-old female patient at Hasan Sadikin Hospital, Bandung, who underwent orthognathic surgery with Le fort I osteotomy technique on the maxilla.

CASE REPORT

A 23-year-old female patient came to the Department of Oral and Maxillofacial Surgery at Hasan Sadikin Hospital Bandung with complaints that the mandible is asymmetric and more forward than the maxillofacial. The patient previously came to the dental office but did not receive any treatment.

After being referred to an orthodontist and then underwent fixed orthodontic treatment and was advised to have orthognathic surgery.

The patient came to Hasan Sadikin Hospital in Bandung, and after consultations with the oral surgeon, it was decided that orthognathic surgery would be performed at Hasan Sadikin Hospital Central Surgery Installation in Bandung. Treatment begins with teeth impressions, panoramic x-ray, cephalometric x-rays, and a head CT scan. The patient is indicated for surgery based on the examination of the profile, model, and cephalometric. The patient's blood pressure, pulse, respiration, and temperature were all within normal ranges when vital signs were examined. Extra oral examination findings showed an asymmetrical face, with a concave profile. Intra-oral examination showed the patient's overjet value of -1 mm. There is a midline shift to the left of 2 mm. The patient has a skeletal class III malocclusion with anterior crossbite. The results of the patient's laboratory examination were within normal ranges, and the results of the Covid examination were negative. The patient was diagnosed with class III dysgnathia and was planned to undergo orthognathic surgery using the le fort I osteotomy technique.

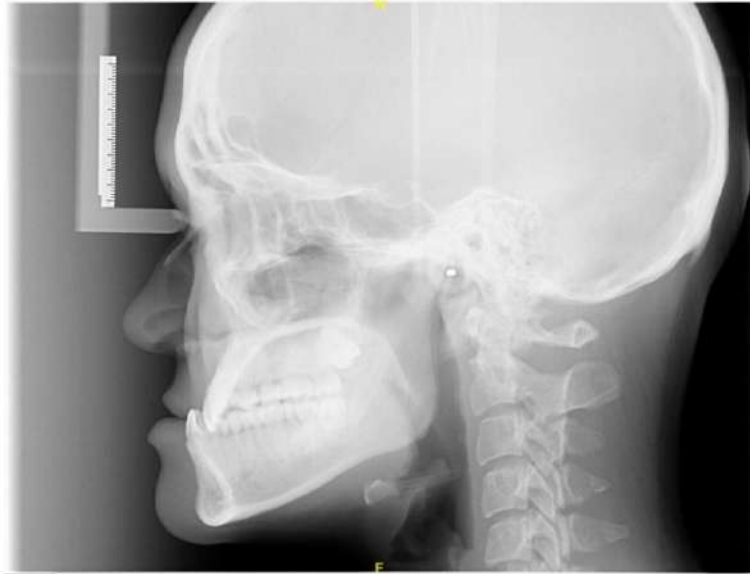

Figure 1: Lateral cephalometric radiograph of the patient.

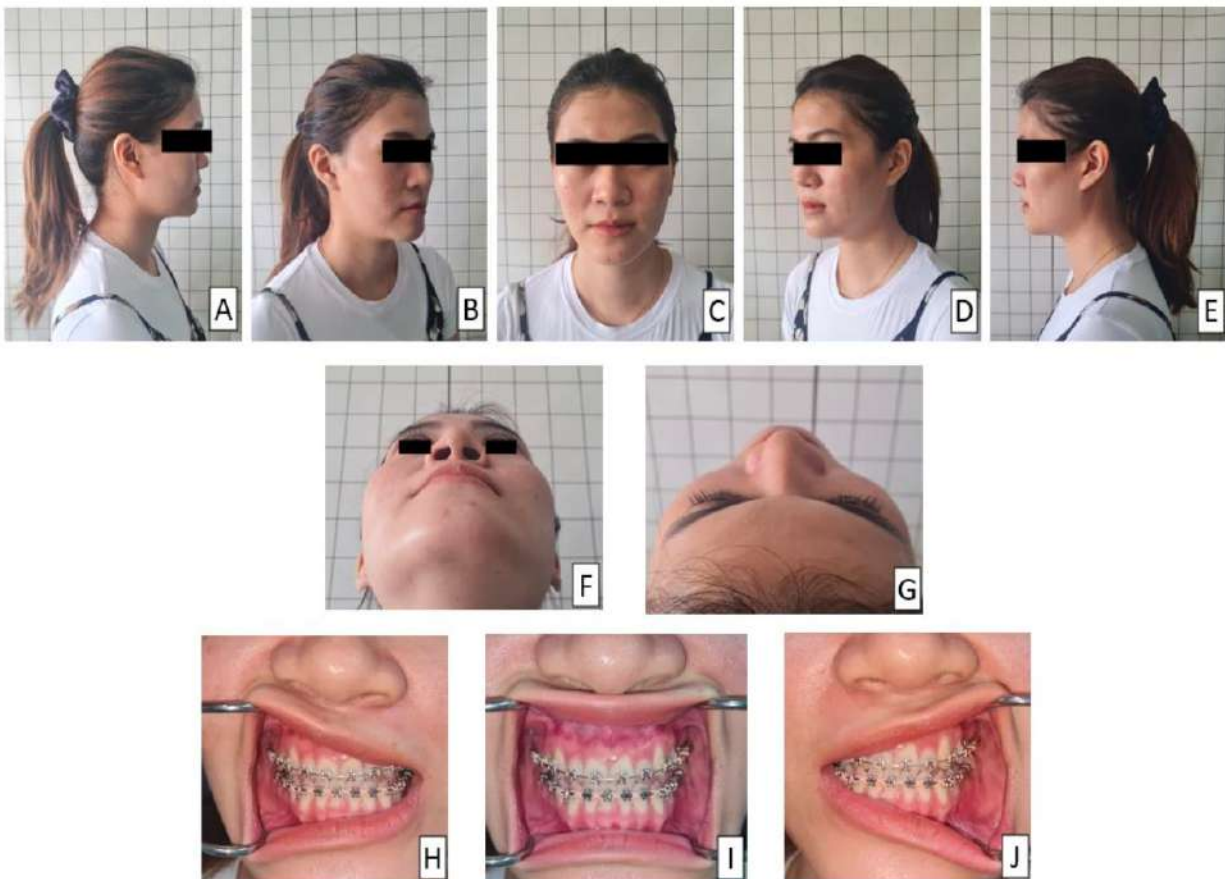


Figure 2: Extra oral clinical photograph of the patient before surgery; A) Patient profile from right side 90°, B) patientProfile from right side 45°, C) Front view of the patient, D) Patient profile from left side 45°, E) Patient profile from leftside 90°, F) Lower view of the patient, G) Upper view of the patient, H) right side intraoral photo, I) Front side intraoral photo, J) Left side intraoral photo

MANAGEMENT

In order to maximize treatment, odontectomy was previously done on teeth 18, 28, 38, and 48 in this patient. A cephalometric analysis was conducted in this case, and the patient's SNB value was 82° , SNA was 74° , and ANB was -8° . In this instance, a correction was undertaken to move the maxilla forward by 3 mm in order to achieve a SNA value of 80° and achieve a normal relationship between the maxilla and the mandible. The next stage, performed surgery using Le fort I osteotomy technique, the procedure begins with an injection of adrenaline in the work area, then continues with an incision. The previous incision line is marked with a surgical marking pen about 10 mm above

the mucogingival line. Incisions in the mucosa, subcutaneous tissue, and periosteum were made using blade no.15 and electrocautery. A subperiosteal dissection is performed of the maxilla anteriorly extending to and on either side of the infraorbital nerve, extending medially to expose the piriform rim and floor of the nose, and extending posteriorly from the pterygomaxillary junction. Nasal dissection is initiated using a periosteal elevator to separate posterior caudal septum with anterior nasal spine. Mucosa is slowly released along the nasal floor, septum, and lateral nasal wall. The wire is then applied to the nasal spine with the intention of drawing it anteriorly after the osteotomy procedure. The osteotomy

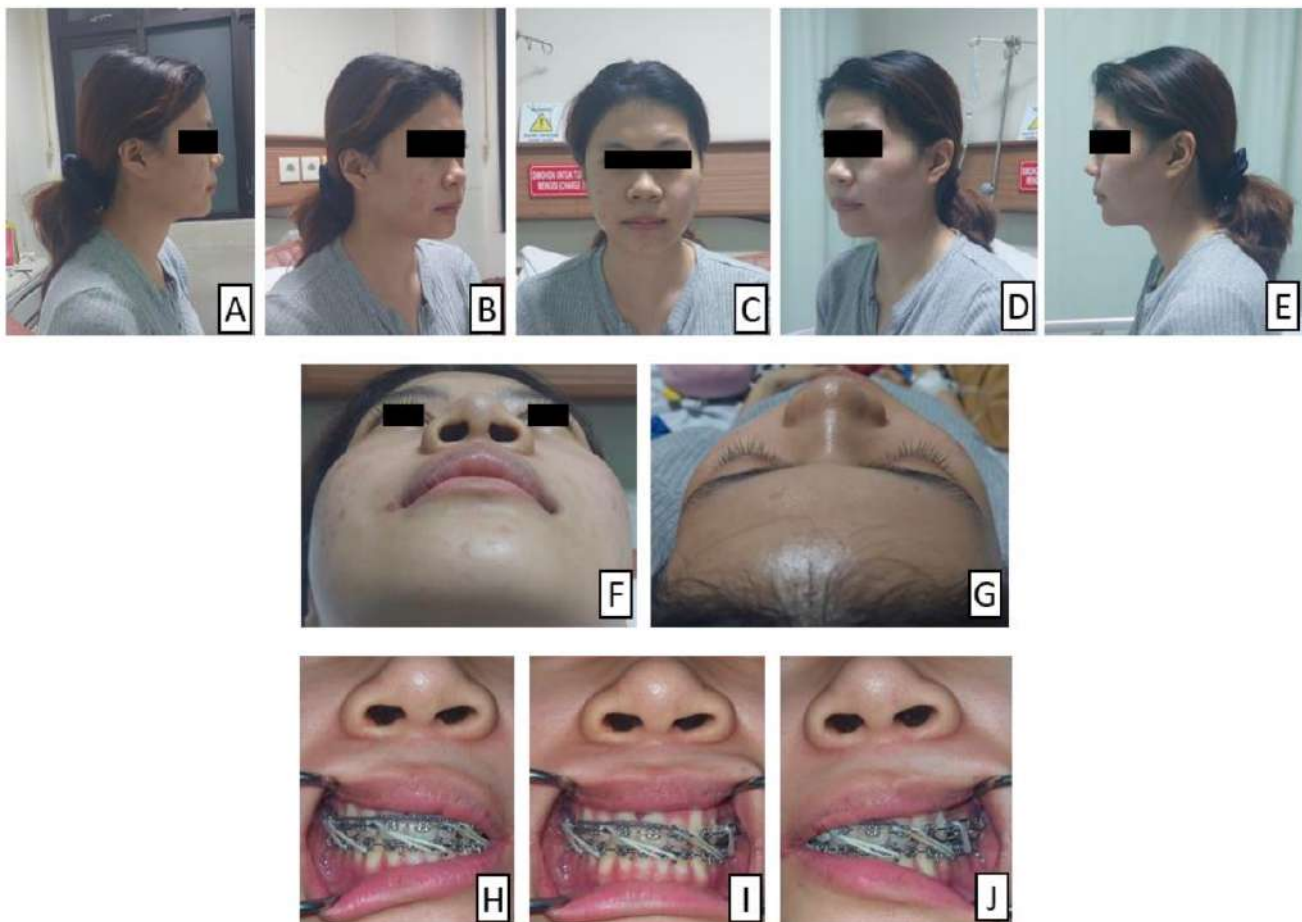


Figure 3: Extra oral clinical photo of the patient on the 2nd postoperative day; A) Patient profile photo from right side 90° , B) Patient profile photo from right side 45° , C) Front view of the patient profile, D) Left view of the patient profile 45° , E) Left side view of the patient profile 90° , F) Lower view of the patient profile, G) Upper view of the patient profile, H) right side intraoral photo, I) Front side intraoral photo, J) Left side intraoral photo

procedure was carried out horizontally by following the lateral, anterior and medial maxillary walls on each side, after which the nasal septum was separated from the maxilla using a nasal separator. Bone splitter used to separate the pterygomaxillary on each side. The action must be ensured not to cause excessive anterior traction. Then, a bone hook and rowe forceps were used in a "down fracture" procedure on the maxillary bone. 0.3 mm wire was used to attach the wafer and secured it to the maxilla bone. Fixation was carried out with an L 1.6 plate of 5 holes each numbering two on the maxilla on the right and left sides, as well as using screw 6 mm as many as 16 pieces. After the fixation process was carried out, the spooling procedure was continued with 0.9% NaCL and ended with suturing. Post-action bite evaluation results are evaluated in order to achieve maximum occlusion and good intercuspal relations. Day 2 postoperatively: Swelling (+),

pain (+), bleeding (-). Blood pressure 110/80 mmHg, pulse 78 times per minute, temperature 36 degrees Celsius, respiration 19 times per minute. Intermaxillary fixation with rubber elastic diameter 4.8 mm was placed. Drug therapy was prescribed with methylprednisolone, ketorolac, omeprazole and ceftriaxone, application of hyaluronic acid gel on the intraoral suture area, and the patient was instructed to follow a liquid diet (Figure 3).

2nd month postoperatively:

Swelling (-), pain (-), bleeding (-). Blood pressure 120/80 mmHg, pulse

80 times per minute, temperature 36.1 degrees Celsius, respiration 19 times per minute. The use of drugs has been stopped. The proper diet and dental hygiene practices were explained. To get the best dentition relationship, the patient was instructed to visit the orthodontist again (Figure 4).

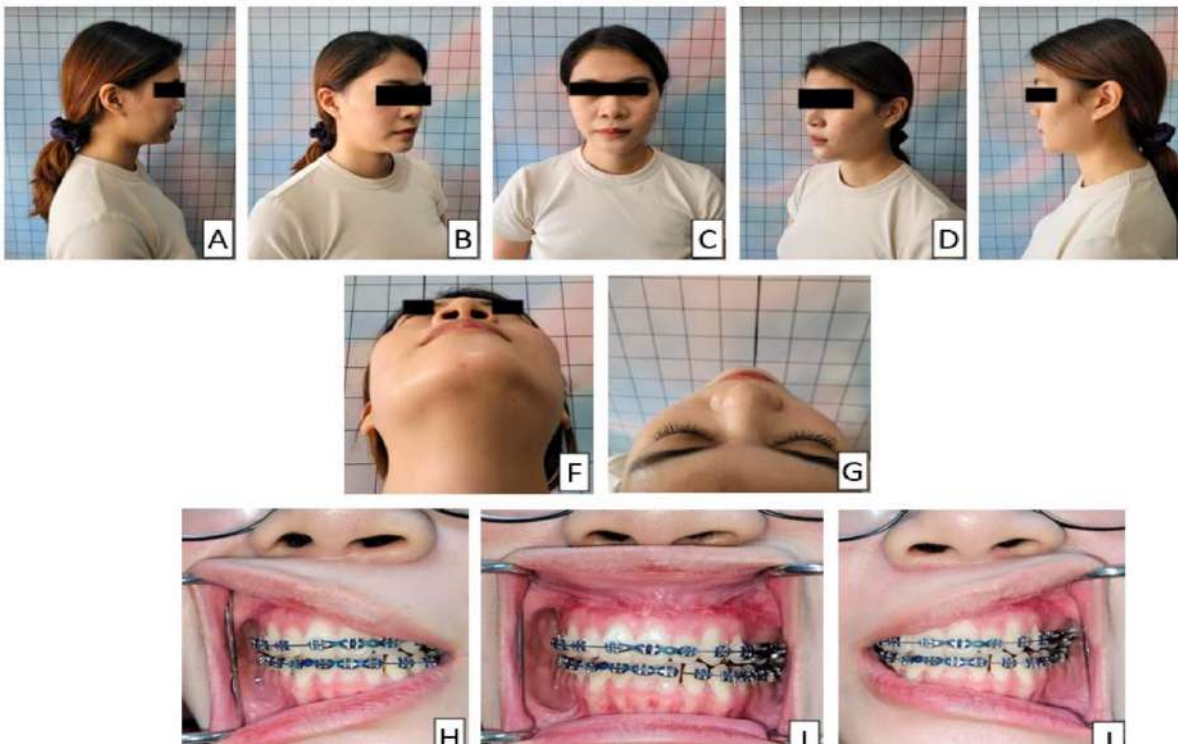


Figure 4: Extra-oral clinical photo of the patient 2nd month postoperatively; A) Patient profile photo from right side 90°, B) Profile profile photo from right side 45°, C) Front view of the patient profile, D) Left view of the patient profile 45°, E) Left side view of the patient profile 90°, F) Lower view of the patient profile, G) Upper view of the patient profile, H) Intraoral of the right side, I) Front side intraoral photo, J) Left side intraoral photo

Discussion

Malocclusion, which can be caused by skeletal, dental, or a combination of both problems, is a deviation in the position of the teeth from their normal state that can affect both function and facial appearance. When considering the relationship between the maxilla and mandible, there are three categories for skeletal classification: class I skeletal (orthognathic), class II skeletal (retrognathic), and class III skeletal (prognathic)¹². Class III dentoskeletal malocclusion or class III dysgnathia shows a retrognathic maxillary and prognathic mandible.¹ In dentistry, class III dentoskeletal malocclusion, where the etiology is influenced by the interaction of environmental and genetic factors is one of the cases with complex management.^{2,3} The prevalence of this type of malocclusion varies in a population, ranging from 0% to 26%.⁴ Treatment is required to repair the abnormality because this abnormality affects how speech, mastication, and appearance of the patients.⁵

Le fort I osteotomy surgical technique was first introduced in 1859 by Von Langebeck.¹⁶ This technique is commonly used to correct malocclusion and maxillary deformity, which is usually used in all cases of midfacial retrusion and maxillary hypoplasia. In this technique, a split action of the hard tissue from the maxilla to the cranium base is carried out with the aim of correcting the maxilla. Le fort I Osteotomy technique can be used to reposition the maxilla anteriorly, posteriorly for a small degree, superiorly and inferiorly so that it can be used to treat class II and III malocclusions, as well as dentofacial asymmetry. Class III malocclusion is one of the most common reasons for orthognathic surgery with le fort I osteotomy technique.^{10,11} It is associated with maxillary hypoplasia, and is more common in patients with orofacial clefts, obstructive sleep apnea and maxillary atrophy.¹⁰

Prognathic mandibular position with an overjet measurement of -1 mm, a median shift of 2 mm to the left, and class III angle malocclusion with an anterior crossbite were all observed throughout the

patient's clinical examination. In this case, the results of cephalometric analysis were obtained with SNB values of 82°, SNA 74° and ANB values of -8°, this analysis was used as a reference for carrying out the Le fort I osteotomy surgery. Le fort I osteotomy was done to protrude the maxilla in order to produce a class I dentoskeletal relationship which aims to improve the masticatory function and aesthetic appearance of the patient. In this case, the postoperative patient's condition showed a significant change in facial profile and jaw relation, this was indicated by the normal overjet value and the occlusion relation showed a skeletal class I relationship. Postoperative complications tend to be minimal, where the swelling that occurs is not accompanied by bleeding or paresthesia. This serves as an indicator of how well the surgery went. Treatment in this case showed a significant improvement in jaw relation, even though there was slightly midline shifting, that need an additional orthodontic treatment to maximize treatment outcomes.

Conclusion

In this case, the patient's complaint of impaired mastication, speech and esthetic function could be resolved without leading to significant postoperative complications. Performing orthognathic surgery requires careful planning, including calculations and proper action plans. It aims to obtain optimal and measurable results. In this case report, a condition of skeletal class III dysgnathia which is corrected by orthognathic surgery using Le fort I osteotomy technique was performed on the maxilla. Although there was slightly shifting on the patient midline dental-skeletal relation because of the preoperative muscle memory, we can still achieve a skeletal class I relation with good intercuspal relation during postoperative examination in this case that uses the le fort I osteotomy surgical technique. To achieve the best results in this case, orthodontic treatment is required as a follow-up procedure.

Reference

1. Jimenez DF. Journal of cranio-maxillofacial. Journal of Cranio-Maxillofacial Trauma. 1998;4(4):6.
2. Perillo L. Early treatment of dentoskeletal Class III malocclusion: SEC III protocol APOS Trends in Orthodontics. [cited 2022 Nov 3]; Available from: www.apospublishings.com
3. Agustina D, Hardjono S, Sri Suparwitri and, Orthodontic Specialist Dentistry Education P, Dentistry F, Gadjah Mada U, et al. Dentoskeletal Class III Malocclusion Camouflage Treatment using the Begg Technique in Adult Patients. MKGK (Clinical Dentistry Magazine) (Clinical Dental Journal) UGM [Internet]. 2015 Dec 1 [cited 2022 Nov 3];1(2):116–21. Available from: <https://jurnal.ugm.ac.id/mkgk/article/view/11979>
4. D'apuzzo F, Nucci L, Strangio BM, Inchingolo AD, Palma G, Minervini G, et al. Dento-Skeletal Class III Treatment with Mixed Anchored Palatal Expander: A Systematic Review. Vol. 12, Applied Sciences (Switzerland). MDPI; 2022.
5. Adnan H, Koshak H. Diagnosis, Complications, And Treatment of Dentoskeletal Malocclusion; Systematic Review [Internet]. Vol. 5, International Journal of Healthcare Sciences. Available from: www.researchpublish.com
6. Agustina D, Hardjono S, Sri Suparwitri and, Orthodontic Specialist Dentistry Education P, Dentistry F, Gadjah Mada U, et al. CASE STUDY Dentoskeletal Class III Malocclusion Camouflage Treatment using the Begg Technique in Adult Patients.
7. Rosen HM. Evolution of a Surgical Philosophy in Orthognathic Surgery. Plast Reconstr Surg. 2017;139(4):978–90.
8. Nafisa AS, Yuza AT, Sadputranto SA. Frequency of dento skeletal abnormalities with orthognathic surgery and osteodistraktion at RSUP Dr. Hasan Sadikin Bandung in 2012-2017. Padjadjaran Journal of Dental Researchers and Students. 2018;2(2):130.
9. Posnick JC. Orthognathic Surgery: Principles and Practice. Elsevier Health Sciences; 2013
10. Naini F. Orthognathic surgery : principles, planning, and practice. Wiley Blackwell. 2017.
11. Monzavi CAE, Morris DE, Patel PK. LeFort I osteotomy. Operative Dictations in Plastic and Reconstructive Surgery. 2016;209–14.
12. Setyowati P, Wayan Ardhana and, PPDGS Orthodontic Studies, Faculty of Dentistry, Gadjah Mada University P, Orthodontics B, Dentistry, Gadjah Mada University F, Denta no J, et al. Treatment of Class III Malocclusion with Class III Skeletal Relations accompanied by Macroglossia Using the Begg Fixed Orthodontic Appliance. Vol. 20, Maj Ked Gi. December. 2013.
13. Sousa CS TR. Complications in orthognathic surgery: a comprehensive review. Journal of CranioMaxillofacial Surgery. 2012;24(2):67–74.
14. Te Veldhuis EC, Te Veldhuis AH, Bramer WM, Wolvius EB KMJ. The effect of orthognathic surgery on the temporomandibular joint and oral function: a systematic review. International journal of oral and maxillofacial surgery. 2017;46(5):554–63.
15. Zaroni FM, Cavalcante RC, da Costa DJ, Kluppel LE, Scariot R RNL. Complications associated with orthognathic surgery: A retrospective study of 485 cases. Journal of CranioMaxillofacial Surgery. 2019;47(12):1855–60.
16. Steinbacher DM. Aesthetic Orthognathic Surgery and Rhinoplasty. 2019.