

STUDY COMPARING THE EFFICACY OF PLATELET RICH PLASMA VERSUS TRIAMCINOLONE IN TREATING TENNIS ELBOW

Pratush Kumar Goyal¹, Anil Kumar Pandey¹, Akhil Bansal², Mohammad Zuber²

¹Senior Resident, Department of Orthopaedics, Gandhi Medical College & Hamidia Hospital, Bhopal, Madhya Pradesh, India

²Associate professor, Department of Orthopaedics, Gandhi Medical College & Hamidia Hospital, Bhopal, Madhya Pradesh, India

Article Info: Received 18 June 2019; Accepted 22 July. 2019

DOI: <https://doi.org/10.32553/ijmbs.v3i7.413>

Address for Correspondence: Dr Pratush Kumar Goyal, Flat No. B-203, Shyam Srusti Apt, VIP Road, Vesu, Surat, Gujarat

Conflict of interest: Nil

Abstract

Background: Lateral epicondylitis is seen more commonly in non-athletes than athletes. Non-operative methods are the mainstay of treatment being effective in more than 95% of cases. Platelet rich plasma (PRP) has shown promising results in many studies as compared to steroid injection & other modes of conservative management. Hence, this study was done to evaluate PRP efficacy in our clinical setup and in the people of age group most commonly being affected.

Methods: This randomized study was conducted at Gandhi Medical College & Hamidia Hospital, Bhopal, for a period of two years from Aug 2015 to Sep 2017 on 60 consenting patients diagnosed as suffering from lateral epicondylitis. Using lottery method for randomization the patients were divided into two groups, based on which the treatment was received. Group –1 with 30 patients received 2 ml of PRP. Group –2 with 30 patients received 2 ml of Triamcinolone injection. The data collected and recorded in the appropriate proforma. Post therapy assessment was done using with Oxford elbow score.

Results: Average age at presentation was 31.11 years, Range of age was from 20 to 40 years. Maximum incidence was in the age group of 35 to 40 years.

Female preponderance was observed in Group 1. Most common presenting complaint was elbow pain seen in 100% of cases. Most common side involved was the dominant side right side involvement was seen in 41 cases and left side in 19 cases. The Oxford elbow score pre-treatment in all the groups was not statistically significant and the Oxford elbow score at the end of 6 weeks, 12 weeks and 24 weeks treatment showed that PRP is better than steroid in control of pain.

Conclusion: Lateral epicondylitis/Tennis elbow is a painful debilitating condition of elbow, which creates disturbance in functional activities. A single injection of PRP at the site of the elbow pain resulted in relief of pain in patients with longer duration as compared to local steroids to other conservative treatments.

Keywords: Tennis elbow, Platelet rich plasma, Steroid, Triamcinolone, Lateral epicondylitis

INTRODUCTION

Lateral epicondylitis commonly known as tennis elbow, remains one of the most perplexing disorders of musculoskeletal system. It is thought to result from overuse or repetitive micro-trauma resulting in a primary tendinosis of extensor carpi radialis brevis (ECRB) muscle with or without involvement of extensor digitorum communis (EDC) and extensor carpi radialis longus (ECRL). Repeated dorsiflexion or

pronation and supination are the most common aetiological factor.¹

Many treatment options are available like use of NSAIDs, steroid injections, physiotherapy but all these have short term relief.^{2,3} Now-a-days, injections of platelet rich plasma (PRP) was proved to be efficacious treatment. PRP is a good source of many growth factors & cytokines like PDGF, TGF-beta, IGF-1, IGF-2, FGF, VEGF, EGF, keratinocyte

growth factors & connective tissue growth factors and found to be one of the new way of treating this painful & disabling condition.⁴

PRP is a concentrate of platelets derived from the patient's own blood. The mechanism of action of PRP therapy in chronic tendinopathies is varied and hypothesized to include angiogenesis, increase in growth factor expression and cell proliferation, increase the recruitment of repair cells and tensile strength. PRP owing to its high content of various growth factors it is found to be more efficacious as a healing agent. However, studies on lateral epicondylitis with PRP treatment have yielded inconclusive results.⁵⁻⁷

Hence, this study was conducted with an aim to explore the efficacy of PRP in patients of tennis elbow in our study place and in the age group most commonly being affected. The main objective of the study was to compare the efficacy of local injection of PRP versus corticosteroids in terms of pain relief assessed by Oxford elbow score.

METHODS

This single blind randomized study was conducted at Gandhi Medical College & Hamidia Hospital for a period of two years from August 2015 to September 2017 on 60 consenting patients of being clinically diagnosed as suffering from tennis elbow/lateral epicondylitis who fulfilled a pre-determined the inclusion & exclusion criteria. The study was initiated after obtaining an ethical clearance from the institution's ethical clearance committee. A written informed consent was taken from the patient or a legal heir before recruiting the patients to the study.

Patients of age group 20-40 years of both the sexes with symptoms typical to lateral epicondylitis with clinically diagnosed as suffering from tennis elbow were included in the study.

Patients more than 40 years or less than 20 years old, patients suffering from elbow pain due to other causes like rheumatoid arthritis, osteochondritis dissecans, crystal arthropathies like gout, radial tunnel syndrome, cervical lesions, shoulder pathology, patients already treated by steroid injection, patients already undergone surgical intervention and any local skin pathology at injection site were excluded from the study.

Using lottery method patients were randomized into two groups consisting 30 patients in each based on which the treatment was received.

- Group 1: 30 patients received 2 ml of the extracted PRP into the affected area
- Group 2: 30 patients received 2 ml of Triamcinolone into the affected area.

Autologous PRP preparation:

Autologous PRP was prepared using the platelet separation system in accordance with the manufacturer guideline. With an 18 G needle, 10 ml of venous blood collected from the participant's cubital vein and transferred into a 50 ml syringe primed with 6 ml of anticoagulant citrate dextrose solution. The collected blood was transferred into the disposable separation tube and spun using a centrifuge at 3200 rpm at room temperature for 15 minutes.

Centrifugal force separates the blood components into three distinct layers based on their particular densities. The heaviest particles, the red blood cells sunk at the bottom of the tube, the least dense constituents the platelet-poor plasma (PPP) move to the top of the tube, while the platelet-rich plasma (PRP) remained at the centre. The whole PPP was extracted into a 30 ml syringe and discarded. Following this, PRP was extracted into a 10 ml syringe. Since an acidic anticoagulant (anticoagulant citrate dextrose solution – solution A [ACD-A]) was added during the collection of venous blood, collected PRP is buffered to increase the pH to normal physiological levels, just before injection. This is accomplished by adding 8.4% sodium bicarbonate solution in a ratio 0.05 ml of sodium bicarbonate to 1 ml of PRP. No activating agent was added to the PRP before administration. The time taken to prepare PRP is about 30 minutes.

After assessment of baseline parameters, the patients were given treatment according to their allotted group and they were evaluated with Oxford elbow score at the time of getting the injection, at the end of 6 weeks, 12 weeks and at the end of 24 weeks.⁸

After the injection for pain relief paracetamol/paracetamol with tramadol was used in all the groups for the first day following which only paracetamol (500 mg) tablets were allowed as rescue medication for a maximum period of one week. Post

treatment physiotherapy was also same in all the groups.

Post injection protocol:

Patients are instructed to limit extensive use of their upper limb for the next 24 hours and to use pain medication only if necessary.

The data was collected and recorded in an appropriate proforma and then transferred to a master chart and then analyzed for statistical significance.

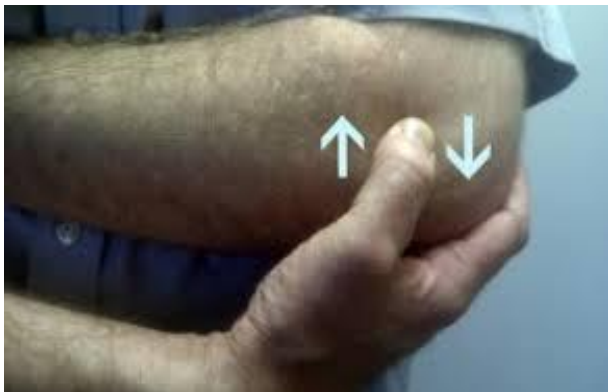

Figure 1: Locating site of injection by eliciting tenderness at lateral epicondyle.

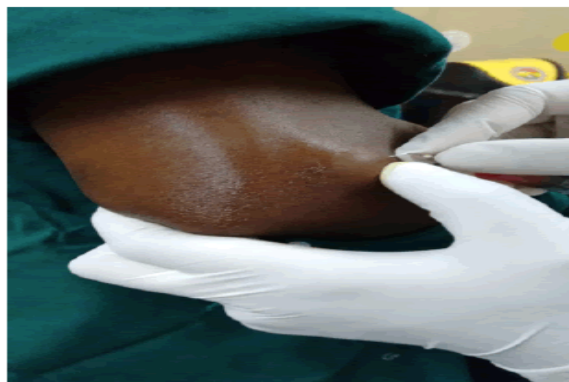

Figure 2: Injecting Technique

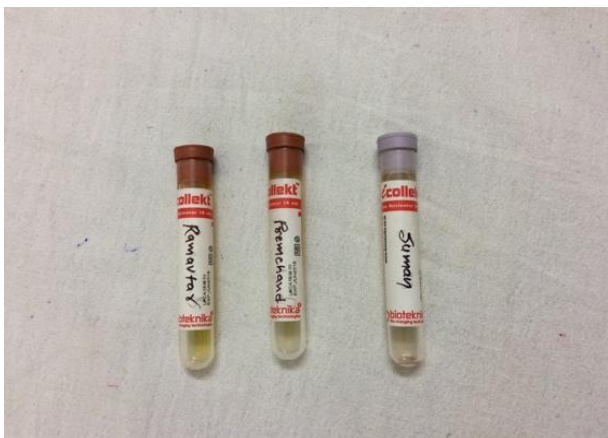

Figure 3: Prepared PRP

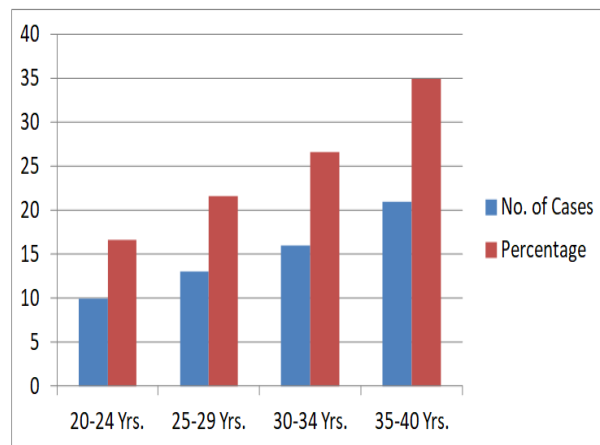
RESULTS

Average Age at Presentation:

Average age at presentation was 31.11 years. Range of age was from 20 to 40 years. Maximum incidence was in the age group of 35 to 40 years.

Table 1:

Age at presentation	No. of Cases	Percentage
20-24 Yrs.	10	16.66
25-29 Yrs.	13	21.66
30-34 Yrs.	16	26.66
35-40 Yrs.	21	35
Total	60	100



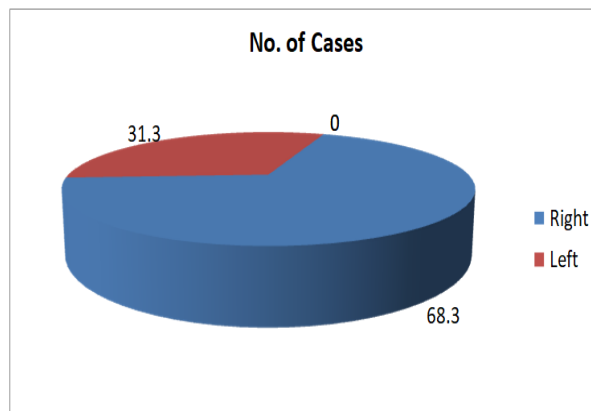
Graph 1:

Status of Affected Arm:

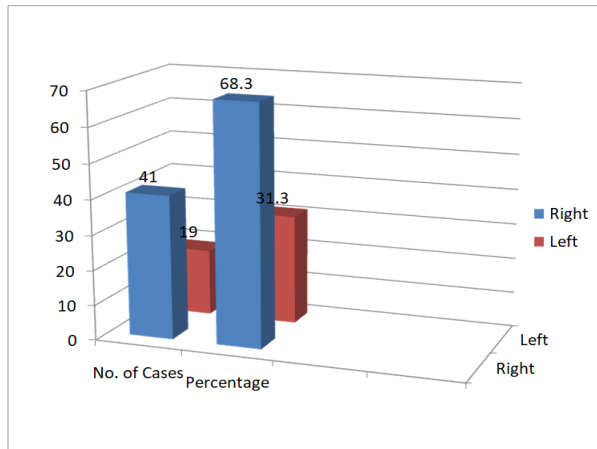
The dominant elbow was predominantly involved i.e. in 41 cases (68.3%) while, the left elbow was involved in 19 cases (31.3%) out of 60. The ratio is 2.1:1

Table 2:

Sr. No.	Status of Arm	No. of Cases	Percentage (%)
1.	RIGHT	41	68.3
2.	LEFT	19	31.3



Graph 2:



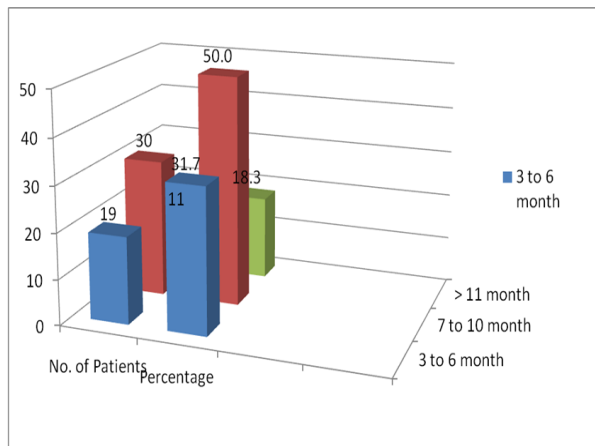
Graph 3:

Duration of Symptoms:

Average duration of symptoms was 7.7month ranging from 3 to 12 months.

Table 3:

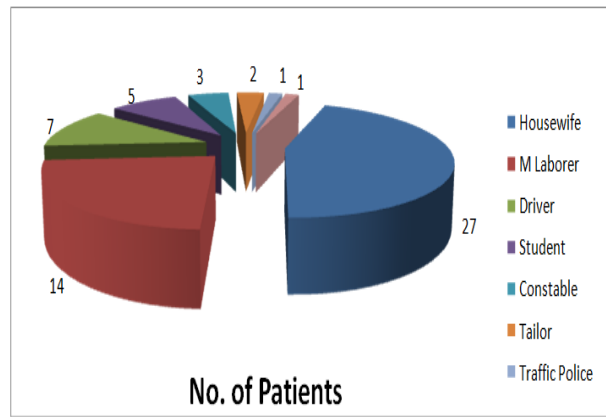
DURATION OF SYMPTOMS	NO. OF PATIENS	PERCENTAGE (%)
3 TO 6 MONTH	19	31.66%
7 TO 10 MONTH	30	50%
> 11 MONTH	11	18.33%



Graph 4:

Occupation of Patients:

In our series 45% (27 patients) were House Wife, 23.33% (14 patient) were Manual Labourer, 11.66% (7 patient) were Driver, 8.33% (5 patient) were Student, 5% (3 patient) were Constable, 3.33% (2 patient) were Tailor, 1.66% (1 patient) was nurse and 1.66% (1 patient) was Traffic policeman by Occupation.

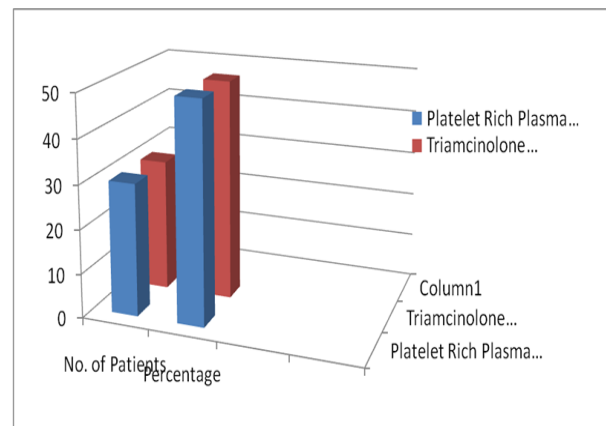


Treatment Modality:

30 Cases out of 60 were treated with Platelet Rich Plasma while equal numbers were treated by Triamcinolone injection.

Table 4:

TREATMENT MODALITY	NO. OF PATINETS	PERCENTAGE (%)
Platelet Rich Plasma Injection (Group I)	30	50
Triamcinolone Injection (Group II)	30	50



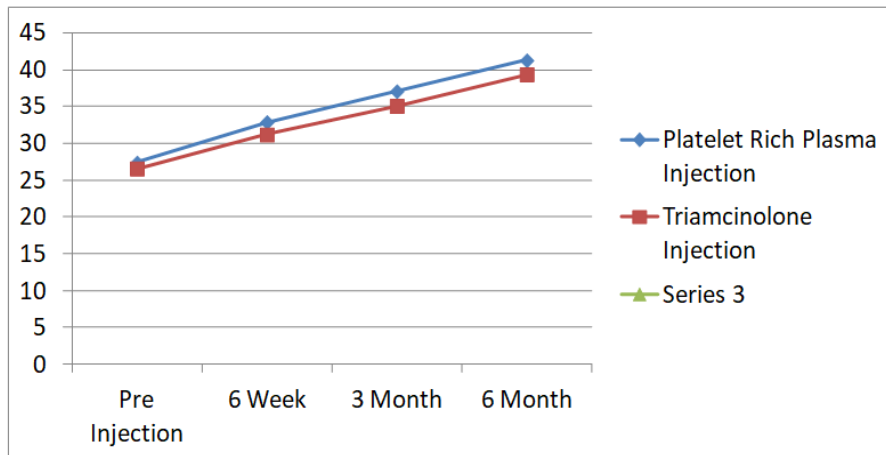
Graph 5:

In our study all patient in both groups reported temporary pain after the injection and oral Tramadol was prescribed to treat pain in all patient for 24 to 48 hours. In 12 (40%) of the patient in group I pain caused by the injection subside within 2 days, in the other 18 patient (60%), the mean duration of pain was 4+ 2 days. Discoloration at the injection site was detected in one patient (3.33%). In group 2 after the first injection pain disappeared within 2 days in 18 patients (60%) and lasted for 3 and 6 days in 12 patients (40%) respectively. No patient developed infection or other complication.

OXFORD ELBOW SCORE (OES)

Table 5:

Platelet Rich Plasma Injection					Triamcinolone Injection			
	Mean	% Increment	P-Value	T-Value	Mean	% Increment	P-Value	T-Value
Pre-Injection	27.4		<0.001	0.404	26.6		<0.001	0.404
6 Week	32.9	20.07	<0.001	0	31.2	17.29	<0.001	0
3 Month	37.1	35.40	<0.001	0.007	35.1	31.95	<0.001	0.007
6 Month	41.3	50.72	<0.001	0.17	39.4	48.12	<0.001	0.17



Graph 6:

DISCUSSION

Lateral epicondylitis (LE) or Tennis elbow is an important condition of the upper extremity with an incidence of up to 4-7/1000 patients per year, having a substantial impact on athletes and workers.⁹⁻¹² Many treatment regimens are available. NSAIDs and corticosteroids are used in traditional medicine but found to be not effective in long term. Physiotherapy had shown some improvement though a sub-cohort of patients remain refractory.^{1,3} But now-a days, Polidocanol, prolotherapy, autologous whole blood and PRP injection therapies have reported promising outcomes for LE and other sports related tendinopathies.¹³

PRP injections consists of activated platelets which discharge bioactive signaling molecules, including three adhesion molecules and seven growth factors.¹⁴ Two large animal studies have recently reported improved healing of repaired dog and porcine cruciate ligaments following PRP therapy.^{15,16}

Chronic elbow pain is a frequent disability in patients and most commonly it is diagnosed as lateral epicondylitis or tennis elbow. Through majority of patients respond to non-surgical treatment, a small minority continues to persist with these symptoms and are labeled as resistant or refractory tennis elbow. In fact a small number of patients (1% to 2%) cannot be treated successfully by non-operative or even operative methods (christian et al)¹⁷.

The average age of patients in this series was 31.45 years. With slight female predominance (F:M =1.06:1). Age group ranged from 20 to 40 years, maximum number of cases occurred in the age group of 35-40 years 35% with peak at 36 years 10%. Edwards et al¹⁸, reported mean age at presentation were 46 years in their study, 14 were male and 14 were female. Connell et al¹⁹, reported a mean age of 41 years of presentation, 66% were male and 44% were female as per their study group of 35 patients. Mishra et al^{20,21}, reported a mean age of 47 years at presentation sex not reported in their study. Verhaar et al⁴, reported mean age 43 years, 59 were male and 47 were female in their

prospected randomized study of 106 patients. Ozturan et al.²², reported mean age at presentation was 45 years. Female were 56%.

In present series Dominant elbow was predominantly involved i.e. in 41 cases (68.3%) while the left elbow was involved in 19 cases (31.3%) out of 60 cases. Ozturan et al.²³, reported dominant elbow affected in 77% cases. Edward et al.¹⁸, reported dominant elbow involvement 78.57% cases. Gani et al.²⁴, reported 22 patients involved the dominant elbow and four patient involved non dominant elbow in their 26 patient study. It is evident from this series that dominant side is more frequently involved.

In present series average duration of symptoms was 7.69 months ranging from 3 to 12 months Connell et al.¹⁹, reported mean duration of symptoms was 13.8 months. Ozturan et al.²³, reported mean duration of symptom 9.7 months. Gani et al.²⁴, reported mean duration of symptoms was 2.1 years. Verhaar et al.²⁵, reported mean duration of symptoms was 33 weeks. So present series has comparatively lesser duration of symptoms, it may be that patient can see orthopaedics consultants directly and in developed countries they have to seek appointment through referral system which takes time.

In present series 45% patient were house wife, 23.3% patient were manual laborer, 11.6% patient were driver, 8.3% were student, 5% were constable, 3.3% were tailor, 1.6% was nurse and 1.6% was traffic police by occupation. Ozturan et al, reported heavy workers were 17% in their series of 57 patient, Bharti et al, reported occupations distribution showed 17 cases of house wife, 5 cases of teachers, 2 cases of Carpenter and 1 shopkeeper in their series of 25 cases. Stahl et al.²⁰, reported twenty seven had a white collar job, fourteen had a job that seldom involved the performance of strenuous duties and seventeen worked as manual labourer, eleven patient were nonprofessional athletes in their fifty eight patient (Sixty elbow) series.

The fact that there is more than one type of treatment options available in treating resistant cases suggests that no single procedure is effective in all patients. Extra corporeal shock wave, laser treatment, botulinum toxin injection, local steroid injection, Altay et al.²⁶, and manipulation under anesthesia Christian et al.¹⁷, have been used by different authors with variable success.

PRP injection for recalcitrant or refractory tennis elbow is based on the histopathological observation that, tennis elbow is not an inflammatory condition, but a fibroblastic and vascular response called angiofibroblastic degeneration more commonly known as tendinosis. This is characterized by invasion of blood vessels, fibroblasts and lymphatics into the symptomatic area of the extensorcarpi radialis brevis, kraushaar et al.²⁷, The injection of PRP is thought to provide the necessary cellular and humoral to induce a healing cascade, Edwards et al.¹⁸.

As depicted in the statistical analysis significant increment occurs in mean Oxford Elbow Score for Platelet Rich Plasma injection group at 6 weeks (32.9), 3 month (37.1), 6 month (41.3) as compared with pre injection Oxford Elbow Score of (27.4) along with p-value less than 0.001.

In present study mean Oxford Elbow Score for Triamcinolone injection was at 6 week (31.2), at 3 month (35.1), 6 month (39.4), as compared with pre injection Oxford Elbow Score (26.6) along with p-value (<0.001).

At 6 weeks in Platelet Rich Plasma injection group there was better (20.07%) increment in mean OES versus 17.29% reduction in Triamcinolone group. At 6 month follow-up 50.72% increment in mean OES in PRP group was seen with significant improvement in pain.

Present series results are comparable to the study of Edward et al.¹⁸ and Connell et al.¹⁹, who showed improvement in VAS score from 7.8 to 2.3 in case of refractory tennis elbow managed by PRP injection.

Connell et al.¹⁹, reported a case series of 35 improved from 6 point at baseline to 0 point on Nirschl's stage at 6-months follow-up (p<0.001).

Suresh SP et al.¹⁶⁴ showed the effect of PRP in medial epicondylitis and found it to be safe and effective in all the patients, they reported that median score improved from 6 points at baseline to 1 point at 6 months follow up (p<0.001) as per Nirschl Scoring System.

The results of PRP are better than Corticosteroid treated patients as per study of Bisset et al.²⁸, who proved that at six weeks follow up 78% of the participants reported success with injections compared with 65% for physiotherapy showing relative risk reduction (RRR) 0.4 (99% CI 0.2 to 0.9) and 27% for wait and watch with RRR 0.7 (99% CI 0.4

to 0.9). They have found that the long term results of steroid injection are worse as compared to physiotherapy alone or wait and watch policy.

PRP injection technique has been refined recently to improve the probability of hitting the area of pathology. Sonographic guided blood injection has been reported to improve clinical outcome by Connell et al¹⁹. It can also be used to monitor the changes to the common extensor origin. The same technique has been used successfully in the treatment of medial epicondylitis by Suresh SP et al²⁹.

Mishra and Pavelko^{30,21} injected platelet rich plasma for chronic elbow tendinosis and at a final follow up of 12-38 months, patients reported 93% reduction in pain compared with the pre injection status.

Edwards and Calandruccio¹⁸, summarized the advantages of PRP injection for the treatment of refractory lateral epicondylitis in their excellent work on the subject. Its application being minimal traumatic, reduced risk of immune mediated rejection, simple to acquire and prepare and inexpensive are the main advantages.

In present study all patients in both groups reported temporary pain after the injection and oral Tramadol was prescribed to treat pain in all patient for 24 to 48 hours. In 12 (40%) of the patients in group 1 and pain caused by the injection subside within 2 days in the other 18 patients (60%) the mean duration of pain was 4+ 2 days. Discoloration at the injection site was detected in 1 patients (3.33%). In group 2 after the first injection pain disappeared within 2 days in 18 patients (60%) and lasted for 3 and 6 days in 12 patients (40%) respectively. Hence corticosteroid group had shown after pain relief by virtue and anti inflammatory effect.

Ozturan et al²³, also showed similar findings in their series and reported that all patients in both groups experienced temporary pain after the treatment and acetaminophen was prescribed to treat pain in all patients for 24 to 48 hours. In 15 (75%) of the patients in group 1, pain caused by the injection subsided within 2 days. In the other 5 patients (25%), the mean duration of pain was 5+2 days. Discoloration at the injection site was detected in 1 patient (5%) in group 2, pain after the first injection disappeared within 2 days in 16 patients (88.8%) and lasted for 4 and 6 days in 2 patients (11.1%) respectively. After the second injection, only 1

patients (5.5%) had join for >2 days the pain lasted for 4 days.

Connell et al³¹, reported that there were no incidences of infection, neurovascular damage or tendon rupture following the autologous blood injection 91% (25/35) of patients reported temporary pain and stiffness following autologous blood injection.

Edward et al¹⁸, reported that there were no occurrence of infection, reflex sympathetic dystrophy, elbow flexion contracture or other adverse events. 7% (2/28) of patients required short term narcotics.

Elaine M Hay et al³², reported local skin atrophy at the lateral epicondyle was observed in only two patient after local steroid injection at six month and one patients at 12 months in their study of 53 patients. Findings are similar to present series and a known complication of steroid, however in PRP injection, this problem is not there.

Gaujoux - viala et al³³, reported in a metaanalysis of 20 randomized control trial of steroid injection at main side effect were transient pain after injection (10.7%) and skin modification (4.0%).

Rupture of tendons following local steroid injection is not uncommon karpman et al³⁴, reported patellar tendon rupture, Cowan et al³⁵, reported bilateral rupture of tendoachilis and other authors have also reported this problem. These patients than need surgical interventions, although rupture at lateral epicondyle is not of much consequence.

In tendinopathies at other sites autologous blood injection has been used successfully (Edward et al¹⁸, in medial epicondylitis and plantar fasciitis, Suresh et al²⁹, in medial epicondylitis, James et al³⁶. in patellar tendinopathies)

Although this has to be explored further by more studies to substantiate the results. Inherent problem in PRP injection group is that is difficult to blind either patient or investigator in regard to withdrawing blood and injecting PRP made from it.

Limitations of the study

The study duration was for two years the tennis elbow is a self-limiting and recurrent disease, the study term was short as to study the recurrences which is the main drawback of this study.

REFERENCES

1. Yadav R, Kothari SY, Borah D. Comparison of Local Injection of Platelet Rich Plasma and Corticosteroids in the Treatment of Lateral Epicondylitis of Humerus. *J Clin Diagn Res.* 2015;9(7):5-7.
2. Croisier JL, Foidart-Dessalle M, Tinant F, Crielaard JM, Forthomme B. An isokinetic eccentric programme for the management of chronic lateral epicondylar tendinopathy. *Br J Sports Med.* 2007;41:269-75.
3. Buchbinder R, Green SE, Youd JM, AssendelftWJ, Barnsley L, Smidt N. Shock wave therapy for lateral elbow pain. *Cochrane Database Syst Rev.* 2005;4:CD003524.
4. Borrione P, Gianfrancesco AD, Pereira MT, Pigozzi F. Platelet-rich plasma in muscle healing. *Am J Phys Med Rehabil.* 2010;89(10):854–61.
5. Mishra A, Pavelko T. Treatment of chronic elbow tendinosis with buffered platelet-rich plasma. *Am J Sports Med.* 2006;34(11):1774–8.
6. Mishra A, Collado H, Fredericson M. Platelet-rich plasma compared with corticosteroid injection for chronic lateral elbow tendinosis. 2009;1(4):366–70.
7. Raeissadat SA, Rayegani SM, Hassanabadi H, Rahimi R, Sedighipour L, Rostami K. Is Platelet- rich plasma superior to whole blood in the management of chronic tennis elbow: one year randomized clinical trial. *BMC Sports Sci Med Rehabil.* 2014;18(6):12.
8. Dawson J, Doll H, Boller I, Fitzpatrick R. The development and validation of a patient-reported questionnaire to assess outcomes of elbow surgery. *J Bone Joint Surg Br.* 2008;90:466-73.
9. Hamilton P. The prevalence of humeral epicondylitis: a survey in general practice. *J R Coll Gen Pract.* 1986;36:464-5.
10. Kivi P. The etiology and conservative treatment of humeral epicondylitis. *Scand J Rehabil Med.* 1983;15:37-41.
11. Ono Y, Nakamura R, Shimaoka M, Hiruta S, Hattori Y, Ichihara G, et al. Epicondylitis among cooks in nursery schools. *Occup Environ Med.* 1998;55:172- 9.
12. Ritz BR. Humeral epicondylitis among gas and waterworks employees. *Scand J Work Environ Health.* 1995;21:478-86.
13. Struijs PA, Smidt N, Arola H, Dijk VC, Buchbinder R, Assendelft WJ. Orthotic devices for the treatment of tennis elbow. *Cochrane Database Syst Rev.* 2002;1:CD00182.
14. Everts PA, Knape JT, Weibrich G, Schönberger JP, Hoffmann J, Overvest EP, et al. Platelet-rich plasma and platelet gel: a review. *J Extra Corpor Technol.* 2006;38:174-87.
15. Anitua E, Andía I, Sanchez M, Azofra J, del Mar Zaldueño M, de la Fuente M, et al. Autologous preparations rich in growth factors promote proliferation and induce VEGF and HGF production by human tendon cells in culture. *J Orthop Res.* 2005;23:281-6.
16. Murray MM, Spindler KP, Abreu E, Muller JA, Nedder A, Kelly M. Collagen-platelet rich plasma hydrogel enhances primary repair of the porcine anterior cruciate ligament. *J Orthop Res.* 2007;25:81-91.
17. Carroll, R. (1981). "Tennis elbow: incidence in local league players." *Sr J Sports Med* 15(4): 250-6.
18. Edwards SG, Calandruccio JH. "Autologous blood injections for refractory lateral epicondylitis". *J Hand Surg Am.* 2003; 28(2):272-278.
19. Connell, D. A., K. E. Ali, M. Ahmad, S. Lambert, S. Corbett and M. Curtis (2006) "Ultrasound-guided autologous blood injection for tennis elbow." *Skeletal Radiol* 35(6): 371-7.
20. Stahl, Shalom MD, Kaufman, Teddy MD. The efficacy of an injection of a steroid for medial epicondylitis. *JBJS* 1997;79(11)648-652.
21. Mishra A, Collado H, Fredericson M. Platelet-rich plasma compared with corticosteroid injection for chronic lateral elbow tendinosis. *PM R.* 2009 Apr;1(4):366-70.
22. Saartok, T. and E. Eriksson (1986). "Randomized trial of oral naproxen or local injection of betamethasone in lateral epicondylitis of the humerus." *Orthopedics* 9(2): 191-4.
23. Ozturan KE, Yucel L, Cakici H, Guven M, Sungur I. Autologous blood and corticosteroid injection and extracorporeal shock wave therapy in the treatment of lateral epicondylitis. *Orthopedics* 2010 Feb;33(2):84-91.
24. Gani NU, Khan HA, Kamla Y, Farooq M, Shah AB (2014) " Long term result in refractive tennis elbow using autologous blood. *Orthop Rev.* 6 (4): 5473.
25. Verhaar, J. A. G. H. Walenkamp, H van Mameren, A O. Kester and A. J van der Linden (1996) "Local corticosteroid injection versus Cyriax-type physiotherapy for tennis elbow " *J Bone Joint Surg Br* 78(1) 128-32.
26. Altay, Gunal and H. Ozturk (2002). "Local injection treatment for lateral epicondylitis." *Clin Orthop Relat Res* (398): 127-30.
27. Kraushaar, B. S. and R. P. Nirschl (1999). "Tendinosis of the elbow (tennis elbow) Clinical features and findings of histological, immunohistochemical, and electron microscopy studies." *J Bone Joint Surg Am* 81(2): 259-78.
28. Bisset, L., A. Paungmali, B. Vicenzino and E. Beller (2005). "A systematic review and meta-analysis of clinical trials on physical interventions for lateral epicondylalgia." *Br J Sports Med* 39(7): 411-22; discussion 411-22.
29. Suresh SP, Ali KE, Jones H, Connell DA. Medial epicondylitis: is ultrasound guided autologous blood injection an effective treatment? *Br J Sports Med.* 2006 40:935-9.

30. Mishra, A and T Pavelko (2006). "Treatment of chronic elbow tendinosis With buffered platelet-rich plasma." *Am J Sports Med* 34(11): 1774-8.
31. Smidt, N., D.A. van der Windt, W.J. Assendelft, W. L. Deville, I. B. Korthals-de bos and L. M. Bouter (2002b), "Corticosteroid injections, physiotherapy, or a wait-and-see policy for lateral epicondylitis: a randomised controlled trial." *Lancet* 359(9307): 657-62.
32. Elaine M Hay, Susan M Peterson, Martyn Lewis, Gillian Hosie, Peter Craft. Pragmatic Randomised Controlled Trial of local corticosteroid injection and naproxen for treatment of lateral epicondylitis of elbow in primary care. 1999; 319: 964-968.
33. Gaujoux-Viala C, Dougados M, Gossec L. "Efficacy and safety of steroid injections for shoulder and elbow tendonitis: a meta-analysis of randomised controlled trials" *Ann Rheum Dis*. 2009 Dec;68(12):1843-9.
34. Snijders, C. J., A. C. Volkers, K. Mechelse and A. Vieming (1987). "Provocation of epicondylalgia lateralis (tennis elbow) by power grip or pinching," *Med Sci Sports Exerc* 19(5): 518-23.
35. Cowan J, Lozano S, Ring D (2007) "Quality of prospective controlled randomized trial. Analysis of trials of treatment of lateral epicondylitis as an example". 89 (8) : 1693-9.
36. James SL, Ali K, Pocock C, Robertson C, Walter J, Bell I, Connell D. "Ultrasound guided dry needling and Platelet Rich Plasma Injection for patellar tendinosis". *Br J Sports Med*, 2007 Aug,41(8)-518-21.