



## ANALYSIS OF LUMBO-SACRAL DISC PROLAPSE NEUROSURGICAL INTERVENTION

Mustafa Jarullah Neamah <sup>1</sup>, Liwa Abdullah Ali <sup>2</sup>, Ihssan S. Nema <sup>3\*</sup>

<sup>1</sup> Department of neurosurgery- AL-Emamian al Kadhimian Medical City-Baghdad, Iraq

<sup>2</sup> Department of neurosurgery- AL-Emamian alKadhimian Medical City-Baghdad, Iraq

<sup>3</sup> Department of Surgery, College of medicine- Alnahrain University, Baghdad, Iraq

**Article Info:** Received 16 October 2018; Accepted 28 October. 2018

**Cite this article as:** Neamah, M. J., Ali, L. A., & Nema, I. S. (2018). ANALYSIS OF LUMBO-SACRAL DISC PROLAPSE NEUROSURGICAL INTERVENTION. *International Journal of Medical and Biomedical Studies*, 2(5).

**DOI:** <https://doi.org/10.32553/ijmbs.v2i5.45>

**Address for Correspondence:** Dr. Ihssan S. Nema (M.B.Ch.B, F.I.B.M.S); Department of surgery, College of medicine, AL-Nahrain University, 10001, Baghdad, Iraq, P.O. Box: 70004

**Conflict of interest:** No conflict of interest.

### ABSTRACT:

**Background:** Low back pain is a common cause of pain and there are many causes. Finding the exact cause of the pain can help guide treatment and management.

**Objective:** To evaluate the clinical presentation, diagnosis and surgical outcome of the treated patients with lumbar-disc prolapse.

**Patients and Methods:** Patients selection done using neuroimaging like plain radiographs and MRI Scan of lumbosacral spine. The surgical procedures applied were laminectomy, foraminotomy and evacuation of herniated disc material. Patients were analyzed postoperatively for outcome according to the symptoms resolved after surgery, objective clinical examinations and imaging studies.

**Results:** Fifty five patients, 25 (45%) males and 30 (55%) females. Predominant clinical presentation were low back pain with radiation to leg 36(65.4%), neurogenic claudication in 15 patients (27%), and neurological deficit (foot drop) 4 about (7.2%). Seventy four percent (about 41) of the herniated disc were found at L4 L5 and L5 S1 levels. Rate of complications were 12.7% (about 7) with 4 cases infections and 3 with dural tear repaired intraoperatively being commonest. Excellent to good surgical outcome were found in 90% (about 50) of the cases.

**Conclusion:** The results of the study depend mainly on selection of patients. Traditional laminectomy and discectomy still play a benefit for major group of patients. Foraminotomy, opening of roots foramen adds a benefit for the results.

**Keywords:** Laminectomy, MRI, disc, prolapse.

### List of abbreviation:

MRI= Magnetic resonance imaging.

L3, L4, L5= lumbar vertebrae number.

S1= Sacral vertebra number.

L.S.S.= Lumbosacral spine.

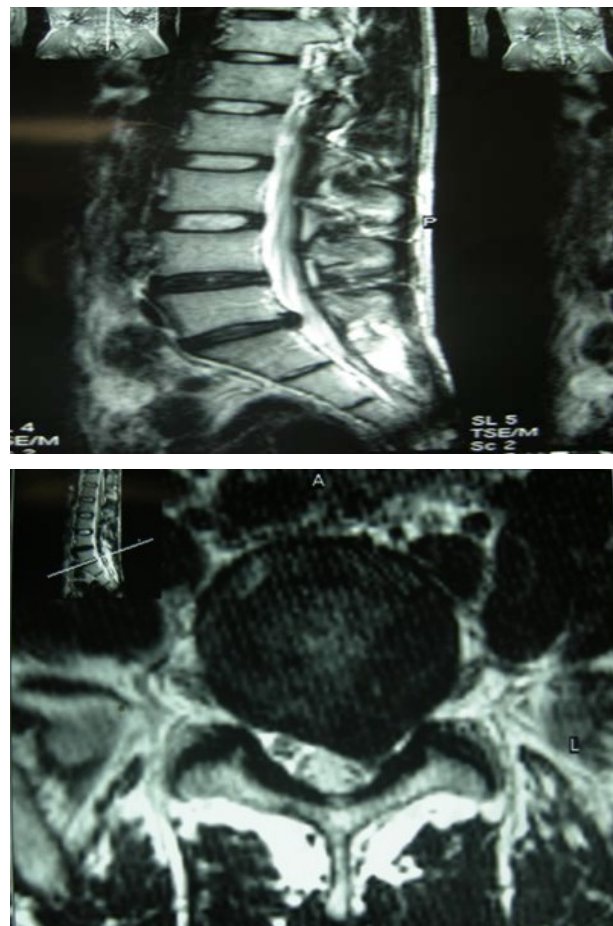
## INTRODUCTION:

Low back pain is a common cause of pain and there are many causes. Finding the exact cause of the pain can help guide treatment and management. Muscle strains, joint related problems, bony pathologies, disc problems and other conditions such as infections are all causes of low back pain. However, a common cause of low back pain can be due to 'degeneration', or wearing out of the lumbar intervertebral discs. The resulting condition is called lumbar disc pain<sup>16, 17</sup>.

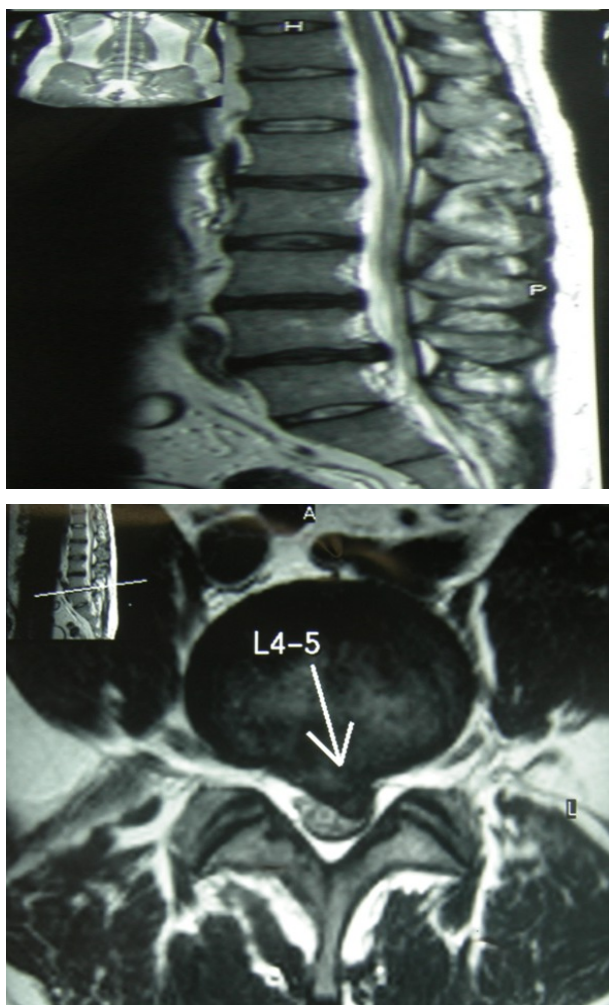
Symptoms of a prolapsed disc may vary, depending on the location of the herniation and the types of soft tissue that become involved. They can range from little or no symptom if the disc is the only part affected, to severe and agonizing **low back pain** that will radiate into the regions served by affected nerve roots that are irritated or compressed by the herniated disc material. Often, prolapsed discs are not diagnosed immediately, as the patients present with undefined pains in the thighs, knees or feet. Other complaints may include sensory changes such as numbness, tingling, muscular weakness, paralysis, **paresthesia** and impairment of the reflexes. If the prolapsed disc is in the lumbar region the patient may also experience **sciatica** which is due to irritation of one of the nerve roots of the sciatic nerve<sup>27, 28</sup>. Unlike a pulsating pain or pain that comes and goes, which can be originated from muscle spasm, pain from a prolapsed disc is usually continuous or at least is continuous in a specific position of the body<sup>30</sup>.

Lower backache with or without sciatica is a major cause of morbidity worldwide. Lumbar disc herniation ("slipped disc") accounts for less than 5% of all low back problems, but it is the most common cause of nerve root pain ("sciatica"). Ninety percent of acute attacks of sciatic pain settle with conservative management. However clinically significant sciatic pain due to disc prolapse occurs in 4-6% of the population<sup>1</sup>. The degeneration of intervertebral disc due to a combination of

factors can result in herniation, particularly at levels of L4 L5 and L5 S1 in more than 90% of the cases. The L3\L4 and L2\L3 accounts for the majority of remaining disc herniations<sup>2</sup>. The presence of painful radiculopathy and other symptoms depend on the site and degree of disc herniation, detailed history, physical examination supplemented by neuroimaging can differentiate herniated lumbar disc prolapse from other causes of low back pain and sciatica<sup>3</sup>. Absolute indications for surgery include altered sphincters function and progressive muscle weakness, but these are rare presentations. The usual indication for surgery is to provide more rapid relief of pain and disability in the minority of patients whose recovery is unacceptably slow. The outcome from disc surgical management depends upon the number of factors; the most important is the careful selection of the patients<sup>4</sup>.



**Figure 1:** L.S.S MRI transverse and saggital section.



**Figure 2:** L.S.S MRI transverse and sagittal section.

**PATIENTS AND METHODS**

A prospective study conducted at the department of Neurosurgery, Alkadhymia Teaching Hospital from 1<sup>st</sup> August 2008 to 1 August 2010. Data of the patients included, age, sex, detailed history of low back pain, findings of clinical examination, details of routine baseline investigations, neuroimaging, and operative procedures, postoperative complications and surgical outcome.

Neuroimaging included plain radiographs and MRI of lumbosacral spine. Patients in the study group presented with various clinical features such as Cauda Equina syndrome, progressive neurological deficit, and profound neurological deficits such as foot drop, severe and disabling pain refractory to 4-6 weeks of conservative

treatment. Conservative treatment consisted of bed rest, drug therapy both steroid and non-steroid anti-inflammatory agents followed by physiotherapy. The criteria for selection of the patients were strictly adhered and standard surgical technique were used (laminectomy, and removal of prolapsed disc material)<sup>4</sup>. All surgeries were performed by the authors. Postoperatively patients were analyzed for outcome according patient symptoms resolved after surgery, objective examinations and radiographic imaging studies including dynamic study to establish vertebral instability.

**RESULTS**

In this study a total of 55 patients were studied and result analyzed with the youngest being of 18 years age and oldest 65 years. Majority of the patients were between 31 to 45 years age group .Table (1).

**Table 1:** Age and sex distribution of patients

Age	Male	Female	No.	%
18-30	6	4	10	18.1%
31-45	14	15	29	52.7
46-65	5	11	16	29%
<b>TOTAL</b>	<b>25</b>	<b>30</b>	<b>55</b>	<b>100</b>

Male to female ratio was 1:1.2. Low back pain with radiation to lower limbs was the predominant mode of presentation as shown in Table 2.

**Table 2:** Patient’s presentation

presentation	No. of patients
Bach pain radiated to lower limb	<b>36</b>
Neurogenic claudication	<b>15</b>
Neurological deficit (foot drop +\- urinary incontinence)	<b>4</b>

**Table 3:** Site of disc prolapse

Site of prolapse	No. of patients
L5\S1	30
L5\4	10
L3\4	4
L2\3	2
Multiple	9

Neuroimaging consisted of mainly plain radiographs and MRI study for all patients.

Figure 1 and 2 reveal herniated discs at different levels on MRI studies of lumbosacral spine. Levels involved for disc prolapses in this study were L4, L5 in 10 patients (18%), L5 S1 in 30 (54.5%), L3 L4 in 4 (7.2%) and L2 L3 in 2 cases (3.6%) and multiple discs prolapse with stenosis 9 cases (16.3). Pre and postoperative complications encountered were dural tears in 3 cases (5.4%), infected disc space (discitis) in 2 cases (3.6%), wound infections in 2 cases (3.6%).

**Table 4:** The outcome

OUTCOME	Number of patients	Percent
Very good result without any complain	28	50.5%
Good result with slight complain	22	40%
no response after surgery	5	9%
TOTAL	55	100%

**DISCUSSION**

Management of lumbar disc herniation has been extensively studied because of its economic impact in the society<sup>1-3</sup>.

**Age group:** affected in this study was between 30 to 45 years, hard workers and the main bread earners of families.

**Level of disc prolapse:** The reported frequency of occurrence of lumbar disc prolapse is highest at L4 \L5 and L5\S1 levels in 90% of the cases<sup>2</sup> while in our study it was seen at these levels in 72.5% of the cases. In the upper lumbar spine extraforaminal space is proportionally larger than in the lower lumbar levels, other factors contributing to disc prolapse are increased mobility of lower segments resulting in earlier degeneration and disc prolapse<sup>6</sup>.

**Diagnostic study:** MRI scan is the gold standard investigation for diagnosis of disc prolapses<sup>7</sup>. The major findings on plain radiographs of the patients with prolapsed disc are a decreased disc height. Radiographs have a limited diagnostic value because degenerative changes are age related and are equally present in symptomatic and asymptomatic cases<sup>7</sup>. MRI scan may show bulging of degenerative discs in asymptomatic cases because of its high sensitivity; therefore any management decision should be based on the clinical findings corroborated by diagnostic test results<sup>8</sup>.

**The treatment:** of lumbar disc prolapse is the most controversial topic in the spine literature, as to whether surgical treatment should be attempted and if so which surgical approach is optimal. Since 1934, surgical treatment for lumbar radiculopathy due to disc prolapse has consisted of laminectomy and removal of herniated material, which is called the standard surgical procedure<sup>4</sup>. In our study, laminectomy and foraminotomy done in most of the patients.

**Outcome:** of disc surgery generally is good; factors that predict the success or failure of lumbar disc surgery have been determined<sup>10, 11</sup>. In general **patient’s selection** appeared to be the most important factor to achieve good results. Approximately 80-90% have good results with traditional laminectomy and discectomy<sup>12, 13</sup>. In our study 50% of the patients had excellent results while 40% good results, most of the patients presented for surgery after utilizing all other modes of therapies for at least 4 to 6 weeks except surgery.

**Complication rate: infection in 7.2%**, two patient with superficial wound infection with got recovery and two with descitis one with very good recovery. A cauda equina syndrome remains an absolute indication for urgent surgery. In the series of Buchner and Schiltenswolf<sup>14</sup>, 12 of 17 patients had a complete recovery of urinary function. In our study 1 out of 4 patients had good control over urinary sphincters while 1 got partial control (stress incontinence) after 6 months of follow up. Motor deficit such as foot drop recovery was very slow and incomplete. One out of 4 cases had good recovery, and 3 had no improvement after 6 months of follow up, indicating long term capacity of recovery. Those three patients had foot drop of more than 3 months duration preoperatively.

### CONCLUSION

1. The results depend mainly on selection of patients.
2. Traditional laminectomy and discectomy still play a benefit for major group of patients.
3. Foraminotomy, opening of roots foramen adds a benefit for the results of laminectomy

### Author contribution:

Dr. Mustafa , Dr. Liwa and Dr. Ihssan did the data collection , analysis and interpretation of data , revising and supervision of manuscript .

**Funding:** Self – funding.

### REFERENCES

1. Frymoyer J. Back pain and sciatica. N. Eng. j. Med., 1988; 318:291-8.
2. Brandenberg GA, Traynelis VC. Disc disease of the spinal column. In: Grossman RG, Loftus CM (eds). Principles of neuro surgery. 2nd ed. 1999, pp.577.593.
3. Klein 3D, Garfin Sr. Clinical evaluation of patients with suspected spine problems. In: Frymoycr JW (ed). The adult spine 2nd ed. Phildeiphia: Lippencoit-Raven, 1997. Pp-319-40.

4. Padua R, Padua S. Romanini E, Ten to 15 year outcome of surgery for lumbar disc hemiations: radiographic instability and clinical findings. Eur, Spine J., 1999; 8:70-81.
5. Mancnab I. Negative disc exploration: an analysis of causes of nerve root involvement in sixty eight patients. J. Bone Joint. Surg. 1971; 53A: 891-903.
6. Schneck CD, The anatomy of the lumbar spondylosis. Clin. Orthop., 1985; 193:20.37.
7. Bell GR, Ross JS. Diagnosis of nerve root compression myelography, computed tomography and MRI. Orthop Clin. North. Am., 1992; 23:405-19.
8. Borden SD, Wiesel SW. Lumbar spine imaging: role in clinical decision making. j. Am. Acad. Orthop. Surg., 1996; 4:238-48.
9. Nachemson A, Zdeblick TA, O' Brien JP. Lumbar disc disease: what surgical treatment is effective? Spine, 1996; 21:1835-8,
10. Junge A, Dvorak J, Ahrens S. Predictors of bad and good outcome of lumbar disc surgery: a prospecLive clinical study with recommendations for screening to avoid bad outcomes. Spine, 1995; 20:460-8.
11. Barrios C, Ahrned M. Arrotegni JI, et al. Clinical factors predicting outcome after surgery for herniated lumbar disc: an epidemiological multivariate analysis. J. Spinal Disord., 1990; 3:205-8.
12. Pappas CT, Harrington T, Sonntag VK. Outcome analysisn 654 surgically treated lumbar disc herinations. Neurosurg., 1992; 30:862-6.
13. Davis RA. Long term outcome analysis of 984 surgically treated lumbar discs, Neurosurg., 1994; 80:415-42l.
14. Buchner M, SchiltenswolfM. Cauda equina syndrome caused by intervertebral disc prolapse, mid term results of 22 patients and review of the literature. Neurothorop. 2000; 27:1 1-27.
15. Epstein NE. Evaluation of varied surgical approaches used in the.management of 170 patients for lateral disc herinations:

- indications and results. 3. *Neurosurg.*, 1995; 83:648-56.
16. Dwain M Daniel, Non-surgical spinal decompression therapy: does the scientific literature support efficacy claims made in the advertising media?, *Chiropractic and Osteopathy*, 2007; 15:7
  17. Stern, Scott D.; Adam S. Cifu, Diane Altkorn (2006). "Back Pain". In Janet Foltin, Harriet Lebowitz, Karen Davis. *Symptom to Diagnosis: An Evidence-Based Guide*. New York: Lange Medical Books/McGraw-Hill. pp. 67–81.
  18. Weinstein JN, Tosteson TD, Lurie JD, et al. "Surgical vs nonoperative treatment for lumbar disk herniation: the Spine Patient Outcomes Research Trial (SPORT): a randomized trial". *JAMA* 2006; 296(20):2441–50. doi:10.1001/jama.296.20.2441. PMID 17119140
  19. Jensen TT, Asmussen K, Berg-Hansen E-MB, et al. First-time operation for lumbar disc herniation with or without free fat transplantation: prospective triple-blind randomized study with reference to clinical factors and enhanced computed tomographic scan 1 year after operation. *Spine* 1996; 21:1072–6.
  20. Bernsmann K, Kramer J, Ziozios I, et al. Lumbar micro disc surgery with and without autologous fat graft. *Arch Orthop Trauma Surg* 2001; 121:476–80.
  21. Gambardella G, Gervasio O, Zaccone C, et al. Prevention of recurrent radicular pain after lumbar disc surgery: a prospective study. *Acta Neurochir* 2005; 92:151–4.
  22. Carlisle E, Luna M, Stou PM, et al. Percent spinal canal compromise on MRI utilized for predicting the need for surgical treatment in single-level lumbar intervertebral disc herniation. *Spine J* 2005; 5:608–14.
  23. Carragee EJ, Han MY, Suen PW, et al. Clinical outcomes after lumbar discectomy for sciatica: the effects of fragment type and anular competence. *J Bone Joint Surg Am* 2003; 85:102–8.
  24. Chatterjee S, Foy PM, Findlay GF. Report of a controlled clinical trial comparing automated percutaneous lumbar discectomy and microdiscectomy in the treatment of contained lumbar disc herniation. *Spine* 1995; 20:734–8.
  25. Malter AD, Larson EB, Urban N, et al. Cost-effectiveness of lumbar discectomy for the treatment of herniated inter-vertebral disc. *Spine* 1996; 21:1048–55.
  26. Geisler FH. Prevention of peridural fibrosis: current methodologies. *Neurol Res* 1999;21(suppl 1):9–22.
  27. Goosens M, Evers S. Economic evaluation of back pain interventions. In: Nachemson A, Jonsson E, eds. *SBU Report on Back Pain*. Stockholm: Swedish Council on Technology Assessment in Health Care: Swedish Council on Technology Assessment in Health Care; 1998.
  28. Greenfield K, Nelson RJ, Findlay GD, et al. Microdiscectomy and conservative treatment for lumbar disc herniation with back pain and sciatica: a randomised clinical trial. In: *Proceedings of the International Society for the Study of the Lumbar Spine*, 2003:245.
  29. Weber H. Lumbar disc herniation: a controlled, prospective study with ten years of observation. *Spine* 1983; 8:131–40.
  30. Weinstein JN, Tosteson TD, Lurie JD, et al. Surgical vs nonoperative treatment for lumbar disk herniation. The Spine Patient Outcomes Research Trial (SPORT): a randomized trial. *JAMA* 2006; 296:2451–9.