

ROLE OF MRI IN DIAGNOSIS OF ROTATOR CUFF TEAR ASSUMING ARTHROSCOPY AS GOLD STANDARD

Dr. Chaturbuj Prasad Swarnkar¹, Dr. Shiv Raj Meena²

¹ Professor, ² Resident

Department of Radiodiagnosis, S.M.S. Medical College & Attached Group of Hospitals, Jaipur, Rajasthan

Article Info: Received 22 August 2019; Accepted 20 September. 2019

DOI: <https://doi.org/10.32553/ijmbs.v3i9.550>

Corresponding author: Dr. Shiv Raj Meena

Conflict of interest: No conflict of interest.

Abstract

Background- Rotator cuff tears are one of the most common causes of shoulder pain for which patients seek treatment. As in our daily work, the shoulder joint is the most frequently used, there is higher chance of having shoulder joint injury. The aim of the study is to compare the efficacy of MRI in diagnosing shoulder pathologies in comparison to arthroscopy, considering arthroscopy as the gold standard.

Methods- 30 Patient with suspected rotator cuff injury patients, between 18-80 years of age was included in the study. MRI of the shoulder joint was done followed by shoulder arthroscopy. The data collected was analysed for the significant correlation between MRI of shoulder and arthroscopic findings by kappa statistics.

Results- The accuracy of MRI in diagnosis of rotator cuff partial tears, was 90%, while sensitivity and specificity was 100.00%, 78.57% and positive predictive value was 84.21% and negative predictive value was 100.00% and accuracy of MRI in diagnosis of rotator cuff full tears, was 86.67%, while sensitivity and specificity was 63.64%, 100.00%) and positive predictive value was 100.00% and negative predictive value was 82.61% in our study.

Conclusion- Our study demonstrates a high sensitivity and specificity for the MRI diagnosis of both partial and full thickness rotator cuff tears and good correlation with arthroscopic findings.

Keywords: Rotator cuff, Shoulder pain, Arthroscopy, MRI.

Introduction:

Shoulder pain can cause significant discomfort and reduce the ability to perform daily routine activities. Thus, with an estimated prevalence of 16-26%, it is third most common cause of musculoskeletal consultation.¹

Arthroscopy is the current gold standard in diagnosing shoulder pathologies. It provides a 20-power magnification, which enhances the direct visualization of the shoulder joint.²

Arthroscopic procedure is invasive and thus carries small risks of complications such as infection, damage to adjacent structures e.g. musculocutaneous nerve or articular cartilage and fluid extravasation. Complications may also arise from the anaesthetic agent.³

MRI has revolutionized the diagnosis of shoulder pathologies. MRI is a proved sensitive, accurate, cost-effective and a non-invasive tool in investigating shoulder pathology⁴.

MRI also provides information on areas not seen in arthroscopy, like the internal structure of the rotator cuff.

Rotator cuff tears are one of the most common causes of shoulder pain for which patients seek treatment. As in our daily work, the shoulder joint is the most frequently used, there is higher chance of having shoulder joint injury. 30-70% of patients having shoulder pain are due to abnormality of rotator cuff.^{5,6}

Thus, MRI before diagnostic and therapeutic arthroscopy may be useful in planning suitable management of shoulder pain.

MATERIALS AND METHOD

Study Area: Patients attending OPD/IPD in Department of orthopaedics and physical medicine and rehabilitation(PMR), SMS Hospital, Jaipur, Rajasthan.

Study Design: Hospital based Cross sectional study.

Study Type: Analytical type of observational study.

Study Period:-Data collection for study was start after approval of plan from the institutional research and review board and ethical committee up to June 2019 or till sample size is achieved, whichever is earlier. Then it was take another 2 months to process the data and dissertation writing.

Study Tool:-Pre tested, Pre designed and semi structured Proforma will be used to collect data.

Equipment: 3.0 tesla MRI from PHILIPS INGENIA

STUDY UNIVERSE

Patient with suspected rotator cuff injury referred to Department of Radiodiagnosis of SMS Medical College & Hospital Jaipur.

INCLUSION CRITERIA

- Patients with clinically suspected rotator cuff tear of shoulder.
- Patients willing to give Informed and written consent for arthroscopy and MRI.

EXCLUSION CRITERIA

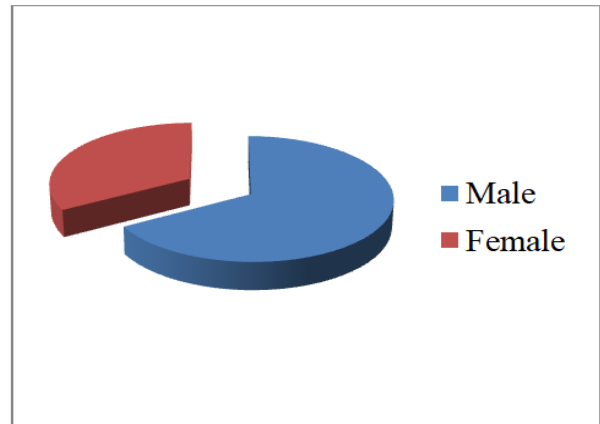
- Patients with rotator cuff tear unfit to undergo MRI like metallic aneurysms clips, pacemakers, metallic vascular clamp placement and history of claustrophobia or any other contraindication to MRI.
- Patients with Shoulder joint fracture in X-ray on affected side.
- Patients with Previous history of recurrent shoulder dislocation on affected side.
- Patients with Previous history of surgery on affected shoulder.

METHODOLOGY

- After approval from institutional ethical committee, patient was selected for study (study population) after applying inclusion and exclusion criteria.
- Prior to examination, written and informed consent was taken from the patient/guardian (in case of minor)
- Patient was selected after applying inclusion and exclusion criteria.
- Prior to MRI, proper precautions will be taken and patient was excluded from study if MRI is contraindicated due to any reason.

RESULTS

In present study mean age of patients was 44.93±17.41 years. The range of patients was 14 to 72 years. 66.67% patients were male and 33.33% patients were female.



Graph 1:

Table 1: Site wise distribution

Hand involved	No of patients	Percentage
Right	24	80.00
Left	6	20.00
Total	30	100.00

80.00% patients were right hand involve and 20.00% patients were left hand involve.

Table 2: Tendon involvement wise distribution

Tendon	No of patients	Percentage
Supra spinatus	18	60.00
Subscapularis	3	10.00
Supraspinatus + infraspinatus	3	10.00
Supra spinatus + Subscapularis	6	20.00
Total	30	100.00

In the present study supraspinatus tendon are more prevalent either as a sole finding or in combination with other tendons like infraspinatus. Supraspinatus tendon affection was found in 60.00% of cases followed by Subscapularis tendon affection was found in 10.00% of acses.

Table 3: MRI finding

MRI Finding	No of patients	Percentage
No tear	4	13.33
Full thickness tear	7	23.33
Partial thickness tear	19	63.33
Total	30	100.00

In our study MRI diagnosed 7 (23.33%) patients with full thickness tear and 19 (63.33%) patients with partial thickness tear.

Table 4: Arthroscopy finding

Arthroscopy finding	No of patients	Percentage
No tear	3	10.00
Full thickness tear	11	36.67
Partial thickness tear	16	53.33
Total	30	100.00

In our study arthroscopy was diagnosed 11(36.67%) patients with full thickness tear and 16 (53.33%) patients with partial thickness tear.

Table 5: The diagnostic parameters of MRI for the diagnosis of partial-thickness tears (PTT)

Sensitivity	100.00%
Specificity	78.57%
Positive predictive value	84.21%
Negative predictive value	100.00%
Diagnostic accuracy	90.00%

The accuracy of MRI in diagnosis of rotator cuff partial tears, was 90%, while sensitivity and specificity was 100.00%, 78.57%) and positive predictive value was 84.21% and negative predictive value was 100.00%

Table 6: The diagnostic parameters of MRI for the diagnosis of Full-thickness tears (FTT)

Sensitivity	63.64%
Specificity	100.00%
Positive predictive value	100.00%
Negative predictive value	82.61%
Diagnostic accuracy	86.67%

The accuracy of MRI in diagnosis of rotator cuff full tears was 86.67%, while sensitivity and specificity was 63.64%, 100.00%) and positive predictive value was 100.00% and negative predictive value was 82.61%.

DISCUSSION

A rotator cuff tear is a tear of one or more of the tendons of the four rotator cuff muscles of the shoulder. A rotator cuff 'injury' can include any type of irritation or overuse of those muscles or tendons, and is among the most common conditions affecting the shoulder ⁷.

The tendons of the rotator cuff, not the muscles, are most commonly involved, and of the four, the supraspinatus is most frequently affected, as it passes

below the acromion. The role of the supraspinatus is to resist downward motion. The supraspinatus resists downward motion while the shoulder is relaxed as well as when carrying weight. Such a tear usually occurs at its point of insertion onto the humeral head at the greater tubercle. Even though the supraspinatus is the most commonly injured muscle of the four muscles in the rotator cuff, the other three muscles that comprise the rotator cuff, the infraspinatus, teres minor, and subscapularis, may also be injured ⁸.

Magnetic resonance imaging (MRI) and ultrasound are comparable in efficacy and helpful in diagnosis although both have a false positive rate of 15 - 20%. MRI can reliably detect most full-thickness tears although very small pinpoint tears may be missed. In such situations, an MRI combined with an injection of contrast material, a MR-arthrogram, may help to confirm the diagnosis. It should be realized that a normal MRI cannot fully rule out a small tear (a false negative) while partial-thickness tears are not as reliably detected ⁹.

In the present study supraspinatus tendon are more prevalent either as a sole finding or in combination with other tendons like infraspinatus. Supraspinatus tendon affection was found in 60.00% of cases followed by Subscapularis tendon affection was found in 10.00% of cases.

Sharma G et al¹⁰ was found that supraspinatus tendon are more prevalent either as a sole finding or in combination with other tendons like infraspinatus. Supraspinatus tendon affection was found in 55% of cases. There was no statistical significant difference in the distribution of pathologies.

Hind Abdulelah Abdulsahib Altahhan et al¹¹ observed that the most commonly involved tendon was supraspinatus tendon which was involved in all 45 patients (100%), followed by infraspinatus tendon involvement in 11 (24.4%) patients, subscapularis tendon involvement in nine (20%) patients.

The accuracy of MRI in diagnosis of rotator cuff partial tears, was 90%, while sensitivity and specificity was 100.00%, 78.57% and positive predictive value was 84.21% and negative predictive value was 100.00% and accuracy of MRI in diagnosis of rotator cuff full tears, was 86.67%, while sensitivity and specificity was 63.64%, 100.00%) and positive predictive value was 100.00% and negative predictive value was 82.61% in our study.

Our results are consistent with literature, with most studies reporting sensitivities and specificities ranging from 85% to 100% for the MRI diagnosis of rotator cuff tears¹².

CONCLUSION

Our study demonstrates a high sensitivity and specificity for the MRI diagnosis of both partial and full thickness rotator cuff tears and good correlation with arthroscopic findings.

REFERENCES

1. Dinnes J, Loveman E, McIntyre L, Waugh N. The effectiveness of diagnostic tests for the assessment of shoulder pain due to soft tissue disorders: A systematic review. NIHR Health Technology Assessment programme: Executive Summaries. 2003; 7(29):iii, 1-166.
2. Nam EK, Snyder SJ. The diagnosis and treatment of superior labrum, anterior and posterior (SLAP) lesions. American Journal of Sports Medicine. 2003; 31(5):798–810.
3. Wall MS, O'Brien SJ. Arthroscopic evaluation of the unstable shoulder. Clinics in Sports Medicine. 1995;14(4):817–839.
4. Tirman PF, Seinbach LS, Belzer JP, Bost FW. A practical approach to imaging the shoulder with emphasis on MR imaging. Orthopaedic Clinics of North America. 1997;28(4):483–515.
5. Mitchell C., Adebajo A., Hay E. and Carr A. Shoulder Pain: Diagnosis and Management in Primary Care. BMJ, 2005; 331: 1124-1128.
6. Macfarlane G.J., Hunt I.M. and Silman A.J. : Predictors of Chronic Shoulder Pain: A Population Based Prospective Study. The Journal of Rheumatology. 1998; 25: 1612-1615.
7. Jana Mayer, DN S, R S, S G, HL N, Mittal R(2012): Magnetic resonance arthrography for assessing severity of glenohumeral labroligamentous lesions. J Orthop Surg.(Hong Kong),20:230–5
8. Collin P, Yoshida M, Delarue A, Lucas C, Jossaume T, Ladermann A (2015): Evaluating postoperative rotator cuff healing: Prospective comparison of MRI and ultrasound. Orthop Traumatol Surg Res., 101(6):S265-8
9. Roy J-S, Braën C, Leblond J, Desmeules F, Dionne CE, MacDermid JC(2015): Diagnostic accuracy of ultrasonography, MRI and MR arthrography in the characterisation of rotator cuff disorders: a systematic review and meta-analysis. Br J Sports Med.,49(20):1316–28.
10. Sharma G. MR Imaging of Rotator Cuff Tears: Correlation with Arthroscopy. J Clin Diagn Res. 2017 May; 11(5): TC24–TC27.
11. Hind Abdulelah Abdulsahib Altahhan, Maha Muhammed Abdelraoof, Marwa Elsayed Abdelrahman. Role of MRI in Diagnosis of Rotator Cuff Tears. The Egyptian Journal of Hospital Medicine (April 2018) Vol. 71 (2), Page 2573-2580
12. Loeffler BJ, Brown SL, Donald FD, Alessandro D, Fleischli JE, Connor PM. Incidence of false positive rotator cuff pathology in MRIs of patients with adhesive capsulitis. Orthopedics. 2011;34(5):e81–e 87.