

CRANIOPLASTY FOR PROSTHETIC CRANIAL RECONSTRUCTION OF SKULL DEFECTS USING PRE-FABRICATED POLYMETHYL METHACRYLATE GRAFTS REINFORCED BY HYDROXYAPATITE PARTICLES INTRAOPERATIVELY IN RURAL POPULATION OF CENTRAL INDIA REGION: A PILOT STUDY

Dr. Sandeep W. Iratwar¹, Dr. Sweta Pisulkar², Dr. Akshay Patil³

¹Consultant, Neurological Surgeon, Professor and Head, Division of Neurosurgery AVBRH, DMIMS Sawangi (Meghe), Wardha, India.

²Associate Professor, Dept. of Prosthodontia, SPDC, DMIMS, Sawangi, Wardha

³Associate Professor, Dept. of Neurosurgery, JNMC, DMIMS, Sawangi, Wardha

Article Info: Received 10 October 2019; Accepted 10 November. 2019

DOI: <https://doi.org/10.32553/ijmbs.v3i11.738>

Corresponding author: Dr. Akshay Patil

Conflict of interest: No conflict of interest.

Introduction

Cranioplasty involves the repair of a cranial defect or deformation. The commoner causes of skull defects include trauma, neurosurgical procedures and infections. Rehabilitation of the deformities related to the cranial vault, as a sequel to trauma is very high and poses a definite challenge to the neurosurgeon. The basic indications for cranioplasty being improvement of disfigured aesthetics and providing protection to the intra-cranial contents has opened an arena for reconstructive surgery of craniofacial deformities. The outcome of craniofacial bone reconstruction is thought to be dependent on surgical skills, quality of adjacent soft tissues, size and location of the bone defect and repair method.^{1,2} The use of autologous bone for craniofacial reconstruction may be restricted due to limited amounts of donor bone. If closure of the craniotomy has to be delayed, the bone flap can be stored either within the patient, for example within the abdominal wall or thigh, or extracorporeally by freezing or freeze-drying. The bone may, however, be absorbed over time or may become contaminated during storage.^{3,4,5} All methods of removing and storing bone are covered by the Human Tissue Act (2007) which prohibits removal and storage of human cells without appropriate consent and also specifies the need for a scheduled, qualifying purpose for all removed tissue. Combined surgical and prosthetic rehabilitation of these structures utilizing craniofacial implants is a viable option that offers several advantages when compared to surgical reconstructive techniques alone.^{1,3,4} This study aims

for Prosthetic cranial reconstruction pre-fabricated methyl methacrylate material graft using hydroxyapatite coated intra-operatively in patients with cranial defect thereby enabling osseointegration of the alloplastic graft reporting to AVBRH, Sawangi (M).

Rationale:

Cranioplasty is accomplished with osteoplastic reconstruction or restoration with alloplastic materials. The main considerations of using patients bone tissue is to keep bone flap "alive" in waiting period. But in most instances it was observed that various factors like viability of bone tissues during preservation, methods of preservation, need for second surgery, infection and rejection of flap, available facilities in the institutes, hospitals for preservation led to discovery of various alloplastic materials as an alternative for reconstruction. Allografts have relied on osteoconduction as the main principle of cranioplasty.^{6,7} In osseointegration, cells do not have to migrate from the surrounding tissues but, with help of hydroxyapatite, can be produced in situ. The proposed study is based on the principle by using hydroxyapatite crystals towards the edges of the defect and mechanical retentive holes placed in the prosthesis enhancing osseointegration and osseointegration. The prosthetic graft ensures excellent esthetics by accurate contouring of the defect avoiding undue damage caused by exothermic reaction during intraoperative material molding.

Applicability:

Cranial defects occur among all ages from a wide variety of causes, such as trauma, infection, congenital malformations, pathology and tumors, and their surgical management leads to skull defects. Repair of cranial defects is indicated to protect underlying brain tissue, to prevent hydrocephalus, pain relief at the defect site, improve cosmetic corrections and minimize patient anxiety. In majority of situations preservation of bone flap is not possible and most of the times, it is rejected because of infection. The ideal material for cranioplasty should be malleable to fit precisely even complicated cranial defects; strong but lightweight; easily securable to cranium; biocompatible and chemically inert; radiolucent; non-ferromagnetic and inexpensive.^{7,8,9} The use of prefabricated heat cured methyl methacrylate resin graft with the application of hydroxyapatite crystals intraoperatively to enhance Osseointegration thereby enhancing osseointegration of the graft can be well justified.

Aim: A Pilot study to determine the effect of Cranioplasty for Prosthetic cranial reconstruction of skull defects using pre-fabricated Polymethyl methacrylate grafts reinforced by Hydroxyapatite particles intraoperatively in rural population of Central India region

Methodology:

The study was conducted in Acharya Vinoba Bhave Rural Hospital in collaboration of Dept. of Neurosurgery, AVBRH, and Dept. of Prosthodontics, Sharad Pawar Dental College and Hospital, Sawangi (M), Wardha.

Setting: Acharya Vinoba Bhave Rural Hospital, Sawangi (M).

Duration: Three years

Sample Size: 60-70 cases

Study Design: Randomized Controlled trial

Method: There are approximately 18-20 patients every year who either report or are referred from around the entire central India region to the Acharya Vinoba Bhave Rural Hospital for cranioplasty. A sequential patient consenting to undergo

cranioplasty by the above-mentioned technique will be carried out. The patients will be selected according to the pre-defined criteria including medical fitness, consent, etc who are fit to be operated for cranioplasty.

The patients will be randomly divided into two groups. One group will undergo treatment by the traditional technique using only the methyl methacrylate allograft whereas another group will undergo the surgery using the hydroxyapatite crystals reinforced allograft.

After the patient will be selected for cranioplasty, the impression of the defect will be made and taking into consideration, the margins and extent of the defect a heat-cured acrylic resin will be fabricated and sent to neurosurgeon for cranioplasty after ETO sterilization of the prosthesis. The hydroxyapatite crystals will be applied all around the edges of bone and graft and the graft will be secured using titanium plates and screws. Hydroxyapatite is a calcium phosphate compound that is found naturally in human bone and teeth but which, since the 1970s, can be produced synthetically by sintering, a process in which the powder is heated until its particles adhere to each other thus producing densification. It is manufactured as a paste providing ease of application and a good fit to the defect, but is now also available as granules and preformed buttons and plates. Most importantly, hydroxyapatite sets without the exothermic reaction of methylmethacrylate. The porosity of the compound encourages the ingrowth of fibro-vascular tissue, which can subsequently ossify.

In the present pilot study, the cranioplasty for 6 patients were carried out based upon the above mentioned protocol and the patients were subjected to recall for the follow up results.

Evaluation: out of all the 6 patients all were reviewed immediately post-operatively, 1 month, 3 months, 6 months and 1 year respectively. The patient were evaluated for absence of any infection and were subjected to CT Scan evaluation of the defect and effect of cranioplasty.

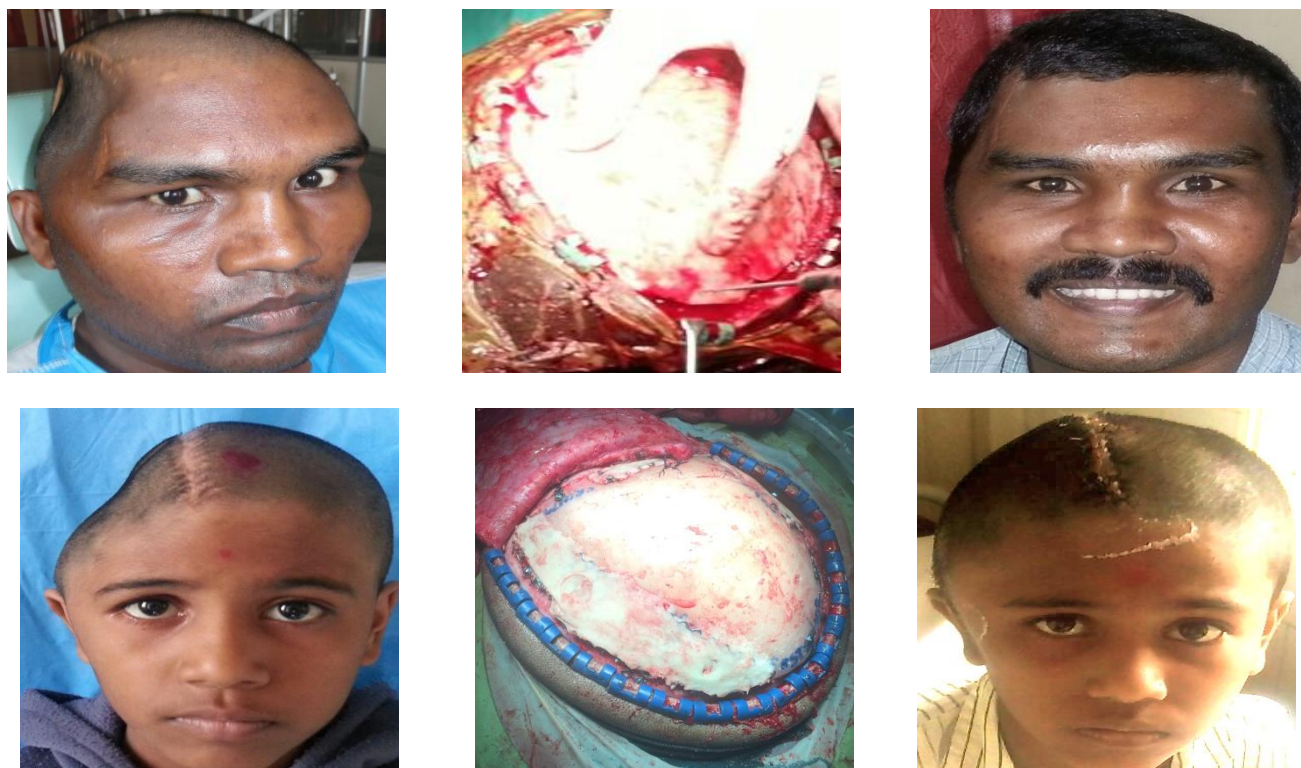


Fig. 1: patients treated in AVBRH using traditional cranioplasty

Outcome: Prosthetic reconstruction of cranial defects using pre-fabricated Polymethyl methacrylate grafts reinforced by Hydroxyapatite particles will

1. Aided in osseointegration with the surrounding tissue
2. Provided enhanced esthetics and improved function by protection of the underlying brain tissues.
3. The reduction in the flap rejection rate due to enhanced integration and osseointegration in contrast to the traditional method of retention using miniplates or implants also enhancing the osseointegration in situ with use of hydroxyapatite crystals.
4. The enhanced treatment could be made available at a relatively economical price thereby improving the feasibility of treatment for population of rural central India region.

The patients from the central India region thus shall definitely be benefited by this project through a multidisciplinary team approach thereby providing successful rehabilitation of the defect and regular follow-up.

Conclusions

In the neurosurgical pathology there are many processes that interested the brain and cranial bones, for various reasons (postsurgical, traumatic, post-replacement process), require resection with rehabilitation or a subsequent time for remaining defect. This is dependant on various factors: the implant must be stable, resistant to daily activities and possibly minor injuries, to effectively protect the brain, not skid spontaneous, to be perfectly biocompatible, does not interfere with vouch skin vasculature and not least to make a adequate cosmetic correction. Now there are a variety of biomaterials that meet these goals. Based upon all the factors the material is best suited for cranioplasty shall be considered. The cranioplasties have been used since early 1950s.^{10,11} Acrylic resin materials have been used as bone substitutes in dentistry, neurosurgery and orthopedics surgery for three decades.^{8,9,12} The prefabricated heat-cured resin implant prosthesis offer many advantages. It saves valuable time in the operating room and better cosmetic results can be achieved as the contours are checked against a master cast and the patient, and the adjustments are made before the patient undergoes surgery. ^{13,14} Excess free monomer is removed because of time of curing and preparation

before implantation. Surgical procedure is relatively simple but requires a well set up infrastructure and obviously a degree of skill. Is it true that high prices are often prohibitive, but the cost-effectiveness, ease of implantation process, significantly reducing operator time and duration of hospital stay makes it preferable.

References:

1. Neurological Surgery. Youmans. 6Th edition (2012), Saunders
2. Maniker A, Cantrell S, Vaicys C. Failure of Hydroxyapatite Cement to Set in Repair of a Cranial Defect: Case Report. *Neurosurgery* 1999; 44(6): 1368-1369.
3. Arun K, Gosain M. Biomaterials for Reconstruction of the Cranial Vault. *Plastic and Reconstructive Surgery* 2005; 116(2): 663-666.
4. Jordan RD, White JT, Schupper N. Technique for cranioplasty prosthesis fabrication. *J Prosthet Dent* 1978; 40:230-3.
5. Aquilino SA, Jordan RD, White JT. Fabrication of an alloplastic implant for the cranial defect. *J Prosthet Dent* 1988; 59:68-71.
6. Hammon WM, Kempe LG. Methyl methacrylate cranioplasty: 13 years experience with 417 patients. *ActaNeurochir (Wien)* 1971; 25:69-77.
7. Yamashima, Tetsumori. Modern Cranioplasty with Hydroxyapatite Ceramic Granules, Buttons and Plates. *Neurosurgery* 1993; 33(5): 939-940.
8. Beumer J, Curtis TA, Firtell DN. Maxillofacial rehabilitation-prosthodontic and surgical considerations. The CV Mosby Company: St. Louis; 1979.
9. Timmous RL. Cranial defects and their repair. In: Youmans JR, editor. *Neurological surgery*. WB Saunders Co: Philadelphia; 1973.
10. Martin JW, Ganz SD, King GE, Jacob RF. Cranial implant modification. *J Prosthet Dent* 1984;52:414-6.
11. Dancev I. Reconstruction of frontal bone of the skull with cartilage implants. *Br J Plast Surg* 1965;18:288-90.
12. Firtell DN, Moore DJ, Bartlett SO. Radiographic grid for contouring cranial prostheses. *J Prosthet Dent* 1971;25:439-45.
13. Gordon DS, Blair GA. Titanium cranioplasty. *Br Med J* 1974;2:478-81.
14. Spence WT. Form fitting cranioplasty. *J Neurosurg* 1954;11:219-25.