

HISTOMORPHOLOGICAL STUDY OF THE UTERUS IN 64 PERIPARTUM HYSTERECTOMY SPECIMENS.

Dr. Gayatri Devi Pukhrambam¹, Dr O. Okendrajit Singh¹, Dr Babina Sarangthem², Dr Kamal Uddin Gauhar³

¹Associate Professor, Department of Pathology, Regional Institute of Medical Sciences, Imphal, Manipur

²Assistant Professor, Department of Pathology, Regional Institute of Medical Sciences, Imphal, Manipur.

³PGT Pathology, RIMS

Article Info: Received 21 December 2019; Accepted 14 January. 2020

DOI: <https://doi.org/10.32553/ijmbs.v4i1.869>

Corresponding author: Dr O. Okendrajit Singh

Conflict of interest: No conflict of interest.

Abstract

Background: Peripartum hysterectomy is a life-saving procedure performed for intractable obstetric haemorrhage. Uterine atony, rupture, abnormal placentation, retained products etc. are common indications. With the rise of caesarean sections, the incidences of peripartum hysterectomies are increasing worldwide. The aim of the present study is to evaluate the histomorphological findings in peripartum hysterectomy specimens received during a five-year period.

Material and Method: In this hospital based cross-sectional study during a five-year period (Jan 2014 –Dec 2018), 64 peripartum hysterectomy specimens received in the department of Pathology, RIMS, Imphal, Manipur were included. The gross and histomorphological findings were evaluated, studied, statistically analysed and compared with other studies.

Results and Observation: The various histomorphological findings were abnormal placentation 28 (43.7%), uterine atony 15 (23.5%), uterine rupture 14 (21.8%), retained placenta/product 6 (9.3%) and subinvolution 1(1.5%). Abnormal Placentation and Placenta cretas were the most common finding in the present study. Pathologies involving the lower uterine segment was seen in more than 50% of the cases. The age ranged from 21 to 45 years, with majority of the cases were in the 30-39years age group. History of previous caesarean section was noted in 20 cases (31.2%). The relative risk of abnormal placentation was 2.5 times higher in those cases with prior history of caesarean section. Rupture was most commonly associated with multiparous women. Co-morbid overlapping features were seen in few cases.

Conclusion: Histopathological diagnosis not only confirmed the clinico-radiological impression, but also highlighted the other co-morbid associations that caused the intractable haemorrhage which warranted a peripartum hysterectomy.

Keywords: Peripartum Hysterectomy, Abnormal placentation, caesarean section, chorionic villi.

Introduction

Peripartum Hysterectomy (PPHy) is one of the life-saving surgical procedures performed for severe intractable obstetric complications especially hemorrhage, when conservative management fails or is non-responsive (1,2). It results in the loss of fertility and is associated with significant maternal morbidity and mortality (3). The rate of peripartum hysterectomy varies between developing and developed countries and its incidence is increasing worldwide ranging from 0.035% to 0.54% (1,2,3). In a South Indian study (4), the incidence was 0.073% while other Indian studies found incidence rates of 0-31% and 0.47 per 1000 deliveries respectively (5,6).

In the past uterine atony and uterine rupture were the most common indications for peripartum hysterectomy. Other indications for PPHy included cervical lacerations, postpartum sepsis, uterine fibroids, invasive cervical cancer, injudicious use of oxytocics, mismanaged and prolonged labour etc (1,2). However, with the increasing rate of caesarean section (CS), the scenario for PPHy has changed. Abnormalities of placentation is rising with the

increasing incidence of caesarean sections (7-12). Many studies have highlighted that if caesarean section continue to increase, the annual incidence of placenta praevia, placenta accrete, maternal morbidity and mortality would rise substantially (8,13).

Placenta creta is characterized by abnormal attachment/ invasion of chorionic villi into the myometrium in the setting of a dysfunctional or absent decidua (14). The placental villi may attach directly to the myometrium (accrete) or invade further into the myometrium (incretta) and rarely penetrate through the uterine serosa (percreta) (15). Torrential bleeding follows when the placenta is detached or separated in the 3rd stage of labour. In fact, placenta creta is now the leading cause of peripartum hemorrhage in many recent studies (1,2,16).

Uterine rupture during pregnancy is a rare event and frequently results in life- threatening maternal and fetal compromise. It can either occur in women with a native unscarred uterus or in a uterus with a surgical scar. Increased risk of complete rupture is associated with previous caesarean section especially in those women with

two or more CS, preterm delivery, high parity, induced or augmented labour and uterine anomalies (12,17,18).

In about 1% of all deliveries, intrauterine tissue which developed during pregnancy persisted even after delivery and hence bleeding occurs due to the inability of the uterus to involute normally because of these retained products of conception. Several risk factors like failure to progress during labour, instrumental delivery and placenta accrete have been implicated (19).

Uterine atony is a well-recognized clinical phenomenon characterized by failure of the uterine smooth muscle to contract and constrict after delivery to create living ligatures around the blood vessels in the placental bed, leading to rapid blood loss. Failure of the uterus to contract may be associated with retained placenta or placental fragments, either as disrupted portions or more rarely as a succenturiate lobe. The retained material acts as a physical block against the strong uterine contraction which is needed to constrict placental bed vessels. Risk factors like multiple pregnancy, polyhydramnios, pre-eclampsia, and chorioamnionitis are associated with contractile dysfunction and hence development of atonic uterus (20).

Due to the paucity of studies on peripartum hysterectomy in this part of the country, this study is an attempt to evaluate the various histomorphological findings of the uterus in peripartum hysterectomy specimens received during a five-year period.

Material and Method

A hospital based cross-sectional study, for a five year period (Jan 2014 to Dec 2018) was carried out in the Department of Pathology, Regional Institute of Medical Sciences, Imphal, Manipur. Out of 1015 hysterectomy cases received, 64 peripartum hysterectomy specimens were selected and included for the study after obtaining ethical clearance from the institutional ethical committee. Peripartum hysterectomies for malignancy and other elective indications or under 24 week's pregnancy were excluded from the study. From the clinical records available, maternal characteristics like age, parity, relevant gestational history, previous cesarean deliveries or any other uterine surgical procedures and the indication for the hysterectomy were recorded. All the uterine specimens were fixed in 10% formalin and were weighed and measurements were recorded.

Careful external examination was done for presence of tears, sutures, hematoma, contraction bands etc. are recorded. For majority of the specimens a complete longitudinal anteroposterior section was usually performed, however few cases required the lateral opening. The uterine cavity was assessed for contents like blood clot, adherent placental tissue or membranes or for

ruptured or discontinuous areas. The lower uterine segment was carefully examined for scars, thinning, incision areas or any other abnormality. Any abnormal area of placentation, haemorrhagic areas or adherent placental tissue or rupture of the uterine wall were identified.

The number of blocks/sections differed for the different cases. Several tissue sections from the caesarean section site, edges of a traumatic rupture, complete and through and through section of the uterine wall in cases of suspected creta cases and also tissue sections from the ragged, irregular haemorrhagic or adherent membrane like tissues were selected and sampled for histopathological processing. The paraffin blocks were sectioned and stained with H & E stain. Microscopic examination was performed for histopathological diagnosis. The various histomorphological findings were analysed and studied. The data were entered into SPSS version 21.0 software. Mean and standard deviation was calculated for quantitative variables while percentages and frequencies were calculated for qualitative variables. Wherever needed relative risk and chi-square test was applied to see the association between proportions.

Results and Observation

A total of 1015 hysterectomy specimens were received during the five-year study period and 64 cases of peripartum hysterectomy cases were included for the study. The age of the patients ranged from 21 years to 45 years with a mean age of 32.8 yrs. More than half of the cases (56.25%) were in the 30-39 years age group and 46 (71.8%) cases were multiparous women. Twenty cases (31.25%) had history of previous caesarean section (LSCS). The most common indication for the hysterectomy was intractable hemorrhage which could not be managed conservatively. The distribution of the histopathological diagnoses (Fig-1) were abnormalities of placentation 24 (43.7%), uterine atony 15 (23.4%), uterine rupture 14(21.8%), retained product/ placenta 6 (9.37%) and subinvolution 1(1.5%)

Abnormal site Placentation and Placenta cretas (28 cases) were the most common finding in the current study constituting 43.7% of the cases. The lower uterine segment placental implantation was seen in 14 cases, out of which 7 cases had previous history of caesarean section. Gross examination of these areas showed an irregular, ragged raw area predominantly on the anterior aspect. Two cases showed a recently sutured incision and 5 cases showed thinned out and fibrotic lower uterine segment. Histological examination of these areas showed deficient interweaving or meshing of myometrial fiber bundles. Collagen bundles with few interspersed muscle bundles were seen in the scarred areas. The histological concordance to the clinical diagnosis of placenta praevia was 100%.

Placenta creta was histologically diagnosed when chorionic villi implant directly on the myometrial fibres or with an intervening fibrinoid layer. The spongy decidua was focally or completely absent, in the 14 cases studied consisting of 3 cases of placenta accreta, 9 cases of placenta increta and 2 cases of placenta percreta (Table-1). Six (6) of these creta cases had previous history of caesarean section. The relative risk (RR) of abnormal placentation and placenta creta was 2.58 times higher in those who had previous history of caesarean section.

Six cases (9.3%) of retained placenta was observed in the present study out of which three cases showed associated Leiomyoma, intrauterine death (IUD) and endometritis respectively. The placental tissues were partially devitalized and admixed with blood clot.

Uterine rupture was characterized by a full thickness disruption of the uterine wall with involvement of the visceral peritoneum (uterine serosa) and uterine scar dehiscence involved the disruption and separation of a preexisting uterine scar. Fourteen cases (21.8%) of uterine rupture were diagnosed during the study period. The mean age of the cases was 33 years with a 100% occurrence in multiparous women (2 or more pregnancies). Majority (78.5%) showed rupture of the lower uterine segment with lesser (21.5%) fundic rupture. Prior history of caesarean section was noted in 2 cases. The ruptured/torn areas were irregular, shaggy and haemorrhagic. Histologically, the normal architecture was distorted and the muscle fibres were disarranged, discontinuous with areas of oedema, haemorrhage and torn blood vessels with fibrin plugs. Fibrotic/scarred areas were more pronounced in the two cases with history of prior caesarean section. Another case showed a submucosal leiomyoma.

Fifteen cases (23.43%) of atonic uterus were diagnosed after exclusion of other findings. The findings of atonic uterus occurred in a slightly younger age group with a mean age of 28.8 yrs and 46.6% were in parity P₁, 4 cases had previous history of CS. Grossly the uterus is enlarged, boggy, oedematous and soft. The myometrium is hypertrophied and hyperplastic with oedema and haemorrhage apparent microscopically. The histologic findings were non-specific and included dilated and partially thrombosed maternal vessels at the implantation site.

A 41 year old, para 4, underwent peripartum hysterectomy after 10 days of delivery and the histopathological findings showed features of subinvolution. Subinvolution of the placental site was the cause of the delayed postpartum bleeding. The histologic findings showed dilated, clustered, myometrial arteries partially occluded by thrombi of various ages and invested with extra villous trophoblasts. The summary of findings of the 64 cases of peripartum hysterectomy are shown in Table 1.

Discussion

Peripartum hysterectomy is a "near miss" maternal event – an intervention performed in life threatening obstetric situations to prevent death (21). The incidence of peripartum hysterectomy varies in different parts of the world ranging from 0.035% to 0.54% (1-4, 16). The rate of peripartum hysterectomy in the present study is 1.59 per 1000 deliveries which is slightly higher than other Indian studies; the increased rate is possibly due to our institute being a referral centre with adequate facility (4,5,6). The mean age of the 64 cases was 32.8 years which was comparable with other studies and the main indication of PPHy was intractable haemorrhage which could not be managed conservatively.

From a histopathologic perspective, a pathologic diagnosis is important so as to explain the indication of peripartum hysterectomy and also to highlight the cause of the hemorrhage. Again the pathological diagnosis also confirmed the clinical or the imaging impression of the case. So, a standardized method for the gross and microscopic pathological examination of peripartum hysterectomy specimens especially for placenta accreta had been proposed (22).

In the present study, aberrations of placentation were the most common histomorphological finding which was comparable with other studies (16,23). Recent epidemiological studies have shown a dramatic rise in the rate of abnormal human placentation, which may be an abnormality in location (placenta praevia) or adherence (placenta accretas). In the current study, 14 cases of implantation in the lower uterine segment were grouped separately from the placenta creta cases as chorionic villi adherence or invasion could not be appreciated. However multinucleated trophoblastic cells were seen in 1/3rd of the cases. Studies have emphasized that placentation occurs more readily in areas of limited decidua, lesser muscle fibres and scarred areas and the lower uterine segment is a favourable site considering the anatomical and physiological limitations of the lower segment (20). Are these harbinger lesions of placenta accreta?? So, further study on the quantification of the trophoblastic cells and the increased invasive characteristics of these cells is needed.

Risk factors for abnormal placentation include previous caesarean section, other previous uterine surgery and advance maternal age (12, 16). The relative risk of abnormal placentation in the present study was 2.58 times higher in those with prior caesarean section and this finding corroborates with other studies (24,25). It has been observed that abnormal adherence and/or placentation occurred where there is a deficit in the uterine wall due to a scarred uterus. It has been hypothesized that either a defect of the biological functions of the trophoblasts or a

defective endomyometrial interface could be responsible for the abnormal adherence and invasiveness of the trophoblastic tissue (14). In vitro studies have suggested that embryos may preferentially implant into areas of uterine scarring because of the lower vascularization and lower oxygen tension (26). Remodelling of blood vessels at the site of the former scar might influence subsequent placental implantation. So, implantation on either a normally healed or a diseased scar would not have the protective effect of the presence of the deciduas thereby leading to failure of placental separation and hence massive haemorrhage or abruption. which might warrant a peripartum hysterectomy (14, 24).

Various researchers have highlighted the major transformations of the uteroplacental circulation like a shift in the placental blood supply from a spiral artery to a larger radial or arcuate artery and also the formation of placental blood lacunae along with hypervascularization patterns seen in the placental bed. These changes could be useful ultrasonographic and MRI findings in placenta accretas (27,28). So, in a systematic review of accreta placentation by Jauniaux E et al (15), they suggested that placenta accretas should be separated into abnormally adherent and abnormally invasive as these were anatomically different entities with different clinical outcomes. Further, they also opined that determining the depth and extension of accreta placentation prenatally by imaging techniques could improve the outcome of this increasingly common major obstetric complication. However, even for experienced pathologist and also because of limited sampling and degenerative changes, identifying or encountering chorionic villi in direct contact or infiltrating into the myometrial fibres could be challenging especially in situations where the utero-placental interface had been distorted by attempted manual placental delivery and/or postpartum uterine curettage. Therefore, Parra-Herran et al (29) have emphasized that, the finding and documentation of deeper invasion of the trophoblasts and infiltration of chorionic villi into the myometrial vascular spaces was highly specific for placenta creta diagnosis. Further, they hypothesized that placental invasion in placenta creta was due, at least partially to transformation of low resistance myometrial vessels leading to subsequent protrusion of villi into their lumens in the context of absent deciduas.

In the present study, difficulty in histopathological categorization into distinct entities was encountered due to the confounding risk factors and the co-morbid overlapping findings. Just to mention a few, rupture with adherent membranes at the lower uterine segment and retained product of conception with atonic features were seen. As in other studies, rupture of the lower lateral uterine segment was more common in multiparous

women (100%). The uterine wall becomes weak due to stretching, tearing or bruising after repeated childbirth, so the chances of rupture increases with every subsequent pregnancy. Again, importance of histological examination of the ruptured site was emphasized by Kelehan P et al (30) as few of the expanded, dilated capillaries and venules may be associated with amniotic fluid embolus or with amniotic infusion and local defibrination thereby alerting the obstetrician for further systemic bleeding. The role of uterine anomalies, scarring due to previous surgery, uterotonic agents, cervical ripening prostaglandins etc. in causing uterine rupture have been extensively reviewed by Nahum et al. (17).

Retained placental fragments were found detached in the uterine cavity or attached to the uterine wall. Irving and Hertig, in their classic study, stated that "placenta accreta is not to be confused with simple retention of the afterbirth either through failure of the normal mechanism of separation in a healthy uterus or through its imprisonment behind an hour glass contraction"(31). So, from the lack of infiltrative features, 6 cases in our study including a case of IUD were clubbed as retained placenta/product, however whether the atonic features seen in 2cases were the cause or the consequence of the retention could not be ascertained.

Uterine atony, seen in 15 cases (23.3%) was diagnosed by exclusion. In an earlier study by Bala R et al (32) in RIMS, the most common indication for peripartum hysterectomy was uterine atony. The reduction in uterine atony cases was probably due to proper execution of antenatal and delivery management guidelines and protocols. In a simultaneous study of atonic uterus and placenta by Hernandez et al (33), features of acute inflammation and infection were the common uterine pathology while in the placenta chorioamnionitis, umbilical vasculitis, chorionic plate vasculitis and funisitis were observed. Ongoing studies on the abnormalities in foeto-maternal relationship and placental factors are still elusive and inconclusive.

Serum biomarkers for prenatal screening for invasive placentation like β -HCG, pregnancy associated plasma protein (PAPP-A), α -fetoprotein, cell free fetal DNA (cffDNA), cellfree placental mRNA etc. are still not widely applicable (34). However, immunohistochemical studies like GATA3 for assessing the amount and the depth of the invasive intermediate trophoblasts could be helpful in categorization of the cases of abnormal placentation especially in placenta cretas (29). Lastly, the placenta wherever possible, needs to be examined to exclude placental etiology.

Conclusion

Histopathological diagnosis not only confirms the clinico-radiological impression, but also highlights the other co-

morbid associations that caused the intractable haemorrhage which warranted a peripartum hysterectomy. The most common histomorphological finding was placentation abnormalities. Prior caesarean

section was the most important risk factor for aberrant placentation. Further study on the role of trophoblasts in conditions of abnormal placentation and other causes of postpartum haemorrhage is needed.

Table 1: Summary of the findings

Histologic diagnosis	No.of cases(%)	Mean age (years)	Parity	h/o prior C/S	Histological features	Other associated findings
Abnormal(site) placentation	14 (21.8)	30.5	Multiparous 71.4%	7	Implantation at lower uterine segment	Scarred areas noted.
Placenta Cretas	14 (21.8)					
a) Placenta Accreta	3/14	35.0	75% multiparous	1 case	Chorionic villi apposed to the myometrium with intervening fibrinoid but with deficient decidua	+/- adherent placental tissue
b) Placenta Increta	9/14	33.5	Multiparous (55.5%)	3 cases	Chorionic villi encroaches/invades the myometrium	+ adherent placental tissue in lower uterine segment
c)Placenta percreta	2/14	35	P1(100%)	2 cases	Chorionic villi infiltrates through and through the myometrium with serosal involvement	Morbidly adherent placenta
Uterine Atony	15 (23.4%)	28.8	P1-46,6% Multi- 53.3%	4cases	Enlarged, flaccid, boggy uterus with odema , congestion , hemorrhage.	Bicornuate uterus +
Uterine rupture	14 (21.8%)	33	Multiparous (100%)	2cases	Lower lateral uterine segment (78.5%) Fundic (21.5%)	+/- adherent membranes +/- scarred areas
Retained placenta/products	6(9.3%)	36.3	Multiparous (66.6%)	1 case	Fragments of placental tissue, membranes, dead foetus	+fibroid +endometritis +atonic features
Subinvolution	1(1.5%)	41	Multiparous	No	Dilated ,partially thrombosed vessels lined by extravillous trophoblasts	

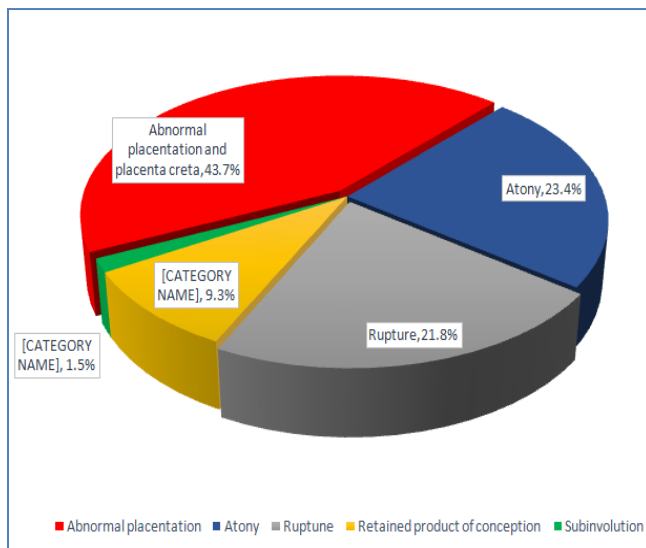


Figure 1: pi chart showing the distribution of the histopathological diagnosis

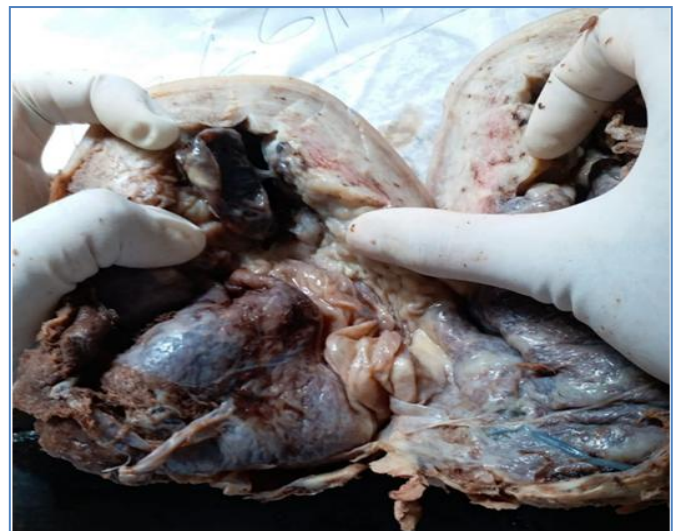

Figure 2: Gross picture of Uterus showing adherent Placenta.

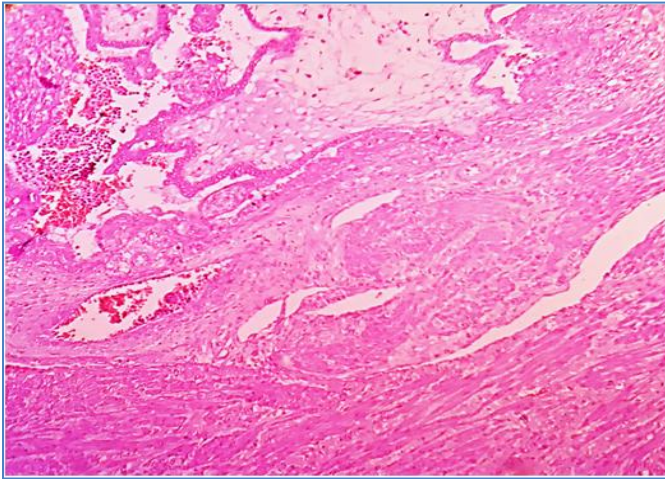


Figure 3: Photomicrograph showing features of placenta increta (infiltrating chorionic villi to the myometrium with absence of decidua). (H & E, X 10)

REFERENCES

1. Umezurike CC and Feyi-Waboso PA. Peripartum hysterectomy in Aba Southeastern Nigeria. *Aust ZN JOG* 2008;48:580-82.
2. Van den Akker T, Brobbel C, Dekkers OM, Bloemenkamp KW. Prevalence, indications, risk indicators and outcomes of emergency peripartum hysterectomy worldwide: a systematic review and metaanalysis. *Obstet Gynecol* 2016;128(6):281-94.
3. Smith J and Nousa HA. Peripartum hysterectomy for primary postpartum haemorrhage: Incidence and maternal morbidity, *J Obstet Gynecol* 2007;27(1):44-7.
4. TahminaS, Daniel M and Gunasegaran P. Emergency peripartum hysterectomy:-A 14 year experience at a tertiary Care Centre in India. *J Clin Diagn Res Sep*;11(9):08-11.
5. Parveen M, Manjeet K, Anju G. Peripartum hysterectomy — A five year study, *J Obstet Gynecol India* vol 58 No6; Nov/Dec 2008:504-6.
6. Agrawal S, Yadav R, Raghunandan C, Dhingra S and Kaur H. Peripartum Hysterectomy in a Teaching Asian *Journal of Medical Sciences* 2013,4(1),5-9.
7. Ananth CV, Smulian JC and Vintzileos AM. The association of placenta praevia with history of caesarean delivery and abortion : a metaanalysis, *Am J Ostet Gynecol* 1997 Nov; 177(5): 1071-8.
8. Solheim KN, Esakoff TF, Little SE, Cheng YW, Sparks TN and Caughey AB, The effect of caesarean delivery rates on the future incidence of placenta praevia, placenta accrete and maternal mortality, *J Matern Fetal Neonatal Med.* 2011 Nov; 24 (11): 1341-6.
9. Klar M, Michels KB, Caesarean section and placental disorders in subsequent pregnancies- a metaanalysis. *J Perinat Med.* 2014 Sep; 42(5):571-83.
10. Wu S, Kocherginsky M, Hibbard JV. Abnormal Placentation: a twenty year analysis. *Am J Ostet Gynecol.* 2005 May; 192(5): 1458-61.
11. Cheng KKN and Lee MMH. Rising incidence of morbidly adherent placenta and its association with previous caesarean section : a 15 year analysis in a tertiary hospital in Hong Kong . *Hong Kong Med J* 2015; 21: 511-7.
12. Fitzpatrick KE, Sellers S, Spark P, Kurinczuk JJ, Brocklehurst P et al . Incidence and risk factors for placenta accrete/increta/ precreta in the UK: A National case-control study. *PLoS ONE* 2012; 7(12) :e 52893. doi: 10. 1371/ journal.pone. 0052893.
13. Marshall NE, Fu R, Guise J-M. Impact of multiple caesarean deliveries on maternal morbidity : a systematic review. *Am J Obstet Gynecol* 2011; 205: 262.e 1-8.
14. Bernirschke K, Burton GJ, Baergen RN. Pathology of the human placenta , 6th Edn, Berlin: Springer- Verlag: 2012.
15. Jauniaux E, Jurkovic D. Placenta accreta: pathogenesis of a 20th century iatrogenic uterine disease. *Placenta* 2012; 33:244-51.
16. Huque S et al. Risk factors for peripartum hysterectomy among women with postpartum haemorrhage analysis of data from WOMAN trial. *BMC pregnancy and childbirth* (2018) 18:186.
17. Nahum GG et al. Uterine anomalies, induction of labour and uterine rupture. *Obstet Gynecol.* 2005 Nov; 106 (5pt2): 1160-2.
18. Ronel D, Wiznitzer A, Sergienko R, Zlotnik A, Sheiner E. Trends, risk factors and pregnancy outcome in women with uterine rupture, *Arch Gynecol Obstet.* 2012; 285:317-21.
19. Weeks AD, Mirembe FM. The retained placenta – new insights into an old problem. *Eur J Obstet Gynecol Reprod Biol.* 2002; 102: 109-110.
20. Khan RV and El-Refaei. Pathophysiology of postpartum hemorrhage and third stage of labour, chapter 13, *A comprehensive textbook of postpartum hemorrhage* , Publisher Paula and David Bloomer 2012, 94-100.
21. Souza JP, Cecatti JG, Haddad SM, Parpinelli MA, Costa ML, Katz L et al .The WHO maternal near –miss approach and the maternal severity index model (MSI): tools for assessing the management of severe maternal morbidity. *PLoS One* 2012;7:e44129.
22. Danheim K, Shaiker SA, Hecht JT. Hysterectomy for placenta accrete: methods for gross and microscopic pathology examination .*Arch Gynecol Obstet* 2016; 293: 951-8.
23. Sharma B, Sikha P, Jain V, Jain K, Bagga R, Suri V. Peripartum Hysterectomy in a tertiary care hospital: Epidemiology and outcomes, Improving outcomesfor

- peripartum hysterectomy: Still a long way to go! *J Anaesthesiol Clin Pharmacol* 2017;33:324-8.
24. Morlando M, Sarno L, Napolitano R, Capone A, Tessitore G, Maruotti GM, Martinelli P. Placenta accrete: incidence and risk factors in an area with a particularly high rate of cesarean section. *Acta Obstet Gynecol Scand* 2013;92:457-460.
 25. Getahun D, Oyelese Y, Salihu HM, Ananth CV. Previous caesarian delivery and risks of placenta previa and placental abruption. *Obstet Gynecol* 2006 Apr;107(4):771-8.
 26. Genbacev O, Zhou Y, Ludlow JW, Fisher SJ. Regulation of human placental development by oxygen tension. *Science* 1997;277:1669-72.
 27. Chou MM, Tseng JJ, Ho ES. The application of three-dimensional color power Doppler ultrasound in the depiction of abnormal uteroplacental angioarchitecture in placenta previa percreta. *Ultrasound Obstet Gynecol* 2002;19:625-7.
 28. Larn G, Kuller J, McMohan M. Use of magnetic resonance imaging and ultrasound in the antenatal diagnosis of placenta accrete. *J Soc Gynecol Investig* 2002;9:37-40.
 29. Parra-Herran C, Djordjevic B. Histopathology of placenta creta: chorionic villi intrusion into myometrial vascular spaces and extravillous trophoblast proliferation are frequent and specific findings with implications on diagnosis and pathogenesis. *Int J Gynecol Pathol* 2016; 35: 456-66.
 30. Kelehan PK and Mooney EE. The Normal and pathologic postpartum uterus. In: a Comprehensive Textbook of Postpartum Hemorrhage 2nd Edn. Sapiens Publishing Dumfriesshire, UK. 2012, 489-98.
 31. Irving C and Hertig AT. A Study of placenta accrete. *Surg Gynecol Obstet* 1937;64:178-200.
 32. Bala R, Devi KP, Singh C. Trend of hysterectomy: A restropective analysis in Regional Institute of Medical Sciences (RIMS). *Journal of Medical society*, vol 29(1); jan- apr 2015, pp4-07.
 33. Hernandez JS, Nuangchamnong N, Ziadic M, Wendel GD Jr, Sheffield JS. Placental and uterine pathology in women undergoing peripartum hysterectomy. *Obstet Gynecol* 2012 Jun; 119(6): 1137-42.
 34. Helena C, Bartels JD, Downy P and Brennan DJ. Placenta accreta spectrum : A review of Pathology, molecular biology and biomarkers. *Disease markers* 2018 doi 1507674, p11.